

**ASPERGILLUS SPECIES IN BRONCHIECTASIS: CHALLENGES IN THE
CYSTIC FIBROSIS AND NON-CYSTIC FIBROSIS AIRWAYS**

Sanjay H. Chotirmall¹ MD PhD and Maria Teresa Martin-Gomez² MD PhD

¹Lee Kong Chian School of Medicine, Nanyang Technological University, Singapore and

²Department of Microbiology, Vall d'Hebron University Hospital, Universitat Autònoma
de Barcelona, Spain.

Correspondence to:

Assistant Professor Sanjay Haresh Chotirmall, Lee Kong Chian School of Medicine,
Nanyang Technological University, Singapore

E-Mail: schotirmall@ntu.edu.sg, Phone: +65 65923934, Fax: +65 65150417

Running title: Aspergillus in bronchiectasis

Key Words: Fungi, Bronchiectasis, Colonization, Infection, Pathogen

Word Count: 5,672 (Abstract 246)

ACKNOWLEDGEMENTS

This research is supported by the Singapore Ministry of Health's National Medical
Research Council under its Transition Award (NMRC/TA/0048/2016) (S.H.C).

Abbreviations: CF: Cystic fibrosis; COPD: Chronic obstructive pulmonary disease; CPA: Chronic pulmonary aspergillosis; CVID: Common variable immunodeficiency; ABPA: Allergic bronchopulmonary aspergillosis; ABPM: Allergic bronchopulmonary mycosis; BAL: Bronchoalveolar lavage; CT: Computed tomography; HRCT: High resolution computed tomography; CXR: Chest radiography; CGD: Chronic granulomatous disease; IPA: Invasive pulmonary aspergillosis; IA: Invasive aspergillosis; Th2: T-helper 2 cells; Ig: Immunoglobulin; rAsp: Recombinant *Aspergillus* antigen; TARC: Thymus activation and regulated chemokine; CFU: Colony forming units; VDR: Vitamin D receptor; OX40L: OX 40 ligand; MBL: Mannan binding lectin; NTM: Non-tuberculous mycobacteria; EAACI: European Academy of Allergy and Clinical Immunology; SAFS: Severe asthma with fungal sensitization.

ABSTRACT

Bronchiectasis is a chronic irreversible airway abnormality associated with infectious agents that either cause or superinfect the airways. While the role of bacteria is well studied, much remains to be determined about fungi in both cystic fibrosis and non-cystic fibrosis related bronchiectasis. The airway is constantly exposed to inhaled ambient molds of which *Aspergillus* represent the most ubiquitous. In a normal healthy host, this situation is of little consequence. The presence of anatomical or immunological abnormalities such as those in bronchiectasis leads to a range of fungal-related pathologies from asymptomatic airway colonization to fungal sensitization, allergic bronchopulmonary aspergillosis or chronic pulmonary aspergillosis. These entities are difficult to recognize, diagnose and treat due in part to a lack of validated biomarkers. Our true understanding of the complex relationships that regulate fungal-host interactions is still in its infancy and, several questions remain. This includes if fungal epidemiology in bronchiectasis is uniform across countries, and to what extent immunopathological mechanisms - related to fungal airway infections - occurs in different disease states. Specific triggers to allergic or infectious responses to *Aspergillus* require further exploration. How transition occurs between allergic and invasive phenotypes and their respective biomarkers is also important. Whether antifungal treatment is warranted in all cases and what the optimal management strategy is, particularly when treatment should commence and its expected duration remains unclear. Further research is clearly necessary and should be prioritized to better understand the clinical effects and impact of *Aspergillus* in the setting of bronchiectasis.

INTRODUCTION

Aspergillus is a ubiquitous genus of filamentous moulds. Their conidia are among the most frequently recovered in ambient air although their spore concentrations illustrate wide variation, ranging from a few units to up to several thousands per m³. This in turn is strongly influenced by environmental factors such as temperature, humidity and the presence of decomposing organic matter [1-3]. Among the species recovered, *A. fumigatus* is the most prevalent [1, 4], although geographical variations in species distribution are observed [5]. Inhaled *Aspergillus* conidia do not pose a risk to the healthy immunocompetent host as a refined machinery of immune defenses impede development of the fungus. The mucociliary escalator acts as an effective innate mechanism of defense that mechanically clears inhaled conidia that become entrapped in the epithelial mucus layer. Alveolar macrophages and neutrophils importantly contribute to this defense against fungal challenges. Any alteration in this delicate balance between host defense and fungal insult may lead to a wide range of pathological scenarios that have been recently reviewed by us and others [3, 6-9].

While the spectrum of fungal pathology has been extensively studied in the severely immunocompromised host (e.g. solid or haematological transplant recipients or patients undergoing chemotherapy), little is actually known about the epidemiology, risk factors, natural history, and clinical management of *Aspergillus*-related syndromes in chronic respiratory diseases such as chronic obstructive airways disease (COPD) and bronchiectasis where *Aspergillus* species have been increasingly detected with an unclear role in disease pathogenesis or progression [10-15]. These syndromes range from

immunological hyper-responsiveness, dysregulation or over-activity to chronic aspergillosis in minimally immunocompromised patients [3, 9, 16].

Bronchiectasis is clinically and pathologically defined as an abnormal irreversible dilatation of the airway secondary to bronchial wall destruction which affects the proximal and medium sized bronchi in either a focal or diffuse pattern. A vicious circle of inflammation and infection is the most widely accepted hypothesis to explain disease origins [17, 18]. Generally, the condition is a common end-point of a wide range of infectious, congenital or mechanical pathologies that interrupt normal immune defences and airway clearance. As a result of the anatomical distortion to the airway, patients with bronchiectasis are at higher risk of recurrent or chronic infections and exacerbations which in turn worsen the disease state in a vicious cycle of infective and inflammatory events [19]. Excluding cystic fibrosis (CF), the most common causes of bronchiectasis are described to be infections, primary ciliary dyskinesia, allergic bronchopulmonary aspergillosis (ABPA) and immunodeficiency, particularly common variable immune deficiency (CVID) [20, 21].

The diverse aetiologies of bronchiectasis interestingly pose the host differing risks of subsequent infections by particular microorganisms. For instance, clear differences in the prevalence of potentially pathogenic microorganisms are seen in patients with CF-related bronchiectasis as compared to bronchiectasis in the non-CF setting [21, 22]. Whereas bacterial infections in both CF and non-CF bronchiectasis have been extensively studied and reviewed [23-28], much less is known about the role of fungi in these settings [6, 29]. Considerable attention has been paid recently to the deleterious role of *Aspergillus* in CF but much work remains to be done related to the spectrum of

Aspergillus-related pathology in non-CF bronchiectasis where it is suspected to be very frequently underdetected and subsequent clinical manifestations underdiagnosed.

THE CLINICAL SIGNIFICANCE OF *A. FUMIGATUS* IN BRONCHIECTASIS

While the burden of bronchiectasis continues to increase internationally, the associated morbidity attributed to fungal colonization of these anatomically distorted airways remains largely unexplored. Most available data are extrapolated from CF and COPD settings or small trials which importantly do not specifically address fungal disease in this specialized patient cohort. While the emerging challenge posed by fungal colonization and infection has been recognized in other chronic respiratory diseases such as asthma and COPD, bronchiectasis has lagged behind [3, 6].

Each day we breath >22,000 times inhaling ~11,000 litres of air in the process. During fungal-rich seasons, this equates to >50,000 fungal spores/m³ of air daily. *Aspergillus* spore size (~ 2-5 µm) permits access to the most distal airways. Immune function and homeostasis then becomes critical to prevent excessive inflammation and tissue damage in response to what is thought to be harmless microorganisms. When the normal airway is exposed to inhaled fungal spores, the pulmonary immune system either permits their presence and the development of an infection or initiates an anti-fungal response to clear them. The chosen path is largely dependent on the underlying state of the host: normal immune function, immune dysfunction or immune hyper-reactivity. This can result in a wide clinical spectrum of *Aspergillus*-associated diseases, any of which may occur in the setting of bronchiectasis [3] (Figure 1).

While *Aspergillus*-associated disease exists along a spectrum of respiratory abnormalities, both structural and immunological, an individual patient can therefore present with one or more *Aspergillus*-associated conditions at any one time and further evolve to alternative types depending on underlying changes in host immunity and its evolution over time (Figure 1). Such clinical challenges make these disease states difficult to identify, diagnose and treat particularly in the setting of bronchiectasis [3, 9].

While the roles of fungi in asthma and other respiratory diseases have been established to have clinical importance, it's theoretical and potentially severe consequences in bronchiectasis warrant attention. Temperate climates additionally likely favour fungal sporulation and increase patient exposure [30]. Hence, the clinician treating patients with bronchiectasis needs to be mindful of fungi as a cause of disease deterioration and exacerbations.

Methods used to detect, identify and analyse fungal communities on mucosal surfaces such as the lung have significantly evolved over the last number of years. Traditional methods of culture coupled to microscopy, biochemical assays and selective media remain in routine use but have been largely superseded by molecular biology (qPCR) and genome sequencing. Next generation sequencing (specifically pyrosequencing of the fungal ITS1 and ITS2 regions) and clone libraries reveal a previously unrecognized diversity of fungi within the human airway that would otherwise remain undetected by use of traditional fungal culture methodologies alone [31-33].

The oral and respiratory tract have been shown to be fungal-rich even in healthy individuals and many ubiquitous environmental fungi can be acquired from food and mouth breathing in patients with anatomically destructive respiratory disease such as

bronchiectasis [34]. Minimal experimental work has been performed in this field to date and none specifically in non-CF bronchiectasis where a high burden of fungal disease is expected similar to that observed in the CF airway [6]. Interestingly, the bronchoalveolar lavage (BAL) of healthy volunteers illustrates minimal fungal ITS amplification in contrast to lung transplant recipients that show markedly elevated fungal concentrations including *Aspergillus* spp. at significant levels; this underlines the relevance of particular host conditions where the amount of fungi found in the airway is studied and, likely introduces a critical factor in understanding the fungal-host relationship. While little is known about the fungal presence in non-CF bronchiectasis airways, evidence suggests that it is likely to be significant considering the disease burden and climates where the disease is most prevalent. In addition, higher risks are conferred by anatomically abnormal airways for fungal acquisition, colonization and subsequent infection that to date has been largely ignored [3, 35-37].

Several questions and unknowns exist regarding *Aspergillus* spp. in a lung with bronchiectasis. A recent publication by the task force of the European Academy of Allergy and Clinical Immunology (EAACI) highlights the significant knowledge gaps existing between fungal infection, the microbiome and bronchiectasis [30]. This document provides a strong platform for the substantial research programmes required to answer such questions in the context of bronchiectasis in both the CF and non-CF settings.

***ASPERGILLUS* SPECIES IN CYSTIC FIBROSIS-RELATED BRONCHIECTASIS**

The most commonly detected filamentous fungi in the CF lung are *Aspergillus* species, with *Aspergillus fumigatus* being most prevalent. Critically, abnormalities in CFTR function, the basis of pathology in CF, influence interactions between the epithelial surface and microorganisms such as *A. fumigatus*. Abnormal immune and inflammatory responses in relation to infection occur in the CF airway which in turn affects cell responses to *Aspergillus*, one key influence of dysregulated CFTR function. *Aspergillus* induces abnormal pulmonary inflammation within the CF microenvironment with emerging evidence of a role for macrophages [38, 39]. Conidial spores are normally cleared by airway epithelium and removed; however, in CF where the epithelial barrier and its associated functions are disrupted, a diminished uptake occurs in conjunction with conidia-induced cellular apoptosis. As a result, germination of the fungi can occur and hyphal forms induce a damaging inflammatory response coupled with pronounced lymphocytic infiltration, excess mucus production and lung injury that culminates in an ongoing cycle of infection, inflammation and pulmonary damage [40].

The main *Aspergillus*-associated clinical manifestation in the setting of CF-related bronchiectasis is ABPA, however aspergilloma or invasive disease may occur albeit rarely (Table 1). *Aspergillus* colonization in the absence of clear sensitization or ABPA remains an important clinical scenario and key area of uncertainty, controversy and ongoing active research. We now review herewith the key relevant *Aspergillus*-associated clinical states, their related pathogenesis and associated therapy for each clinical manifestation relevant to the CF-state and relate this to our understanding of the organism from a molecular, cellular and immunological perspective.

ABPA results from a hypersensitivity response to *Aspergillus* antigens and remains the most prevalent manifestation of *Aspergillus*-associated pathology within the CF airway. Immunologically, ABPA is driven by a T-helper 2 (Th2) cell mediated response and is associated with release of IL-4 and IL-10 which in turn induce production of immunoglobulins G and E (IgG and IgE) specific to *Aspergillus*. Pro-inflammatory mediators, cytokines and eosinophils all then infiltrate the bronchial epithelia and promote further damage [41]. Exact pathophysiological mechanisms are multifarious and incompletely understood; however the host's ability to clear conidia and genetic predisposition may influence likelihood or preponderance for ABPA [42]. It has been suggested the dendritic cells may have an important role in ABPA pathogenesis by promoting IL-10 release and cell susceptibility to IL-4. Recurrent ABPA in itself is a cause of bronchiectasis which over time can progress to fibrosis causing significant remodeling of the airway. In most cases the CF airway is colonized with several bacteria which in itself are an additional risk factor for ABPA [43].

It remains challenging to assess comparative data between CF centers internationally particularly in terms of ABPA occurrence. This is because of the clinical difficulties and specific criteria used in making a diagnosis of CF-ABPA. Published rates of occurrence of both *Aspergillus* isolation and ABPA varies considerably between institutions with sputum culture positivity ranging between 15-50% and ABPA rates ranging from 1-10% [44, 45]. A key point particularly from a clinical perspective is that the frequency of *Aspergillus* identification from sputum shows no correlation with CF-ABPA [45]. Making the CF-ABPA diagnosis is challenging because of indistinguishable clinical, radiological, microbiological and immunological features which in most cases

cannot be differentiated from bacterial exacerbations. It is therefore only following a failed course of anti-microbial therapy that CF-ABPA is considered. To assist caregivers and confront some of these diagnostic issues, an international consensus conference addressing CF-ABPA classical and minimal diagnostic criteria was arranged; however despite such guidelines, many cases of confirmed CF-ABPA fall outside of these criteria, outlining the importance of identifying alternative and adjunctive methods to aid clinicians identify cases of CF-ABPA [45, 46].

The search for potential CF-ABPA biomarkers has therefore been a major focus of most active research in the field [47]. Recombinant *Aspergillus* antigens (rAsp) allow distinguishing the sensitization (rAsp1 and -3) and CF-ABPA (rAsp4 and -6) states. However, their reliability and reproducibility have been questioned [48]. Specific anti-*Aspergillus* IgE targeted against the allergens are useful in suggesting ABPA but critically cannot distinguish the sensitization state from CF-ABPA [49]. Other adjunctive proposed diagnostic tools include anti-*Aspergillus* IgG; however, reliability again has been a concern. Fluctuating levels coupled to absence in many confirmed CF-ABPA cases make such approaches less attractive and furthermore cannot delineate the sensitization state. The lack of standardization between individual cases and centers further limits the use and comparative ability of these proposed markers of disease [50-52]. One emerging Th2 cytokine and potential marker of disease is thymus- and activation-regulated chemokine (TARC). It is described to increase in early CF-ABPA, even preceding IgE, to correlate positively with rAsp4 levels and inversely with lung function and to be promising in reflecting treatment response [41, 53]. An alternative marker of major interest for our group and others is the basophil surface marker CD203c.

Physiologically basophils are primed and hyper-responsive to *A. fumigatus* allergen stimulation. Using flow cytometry, we and others have assessed baseline CD203c levels and illustrate they are up-regulated in CF-ABPA and that rAsp1 exposure augments this up-regulation in CF-ABPA [54, 55]. Our group has also recently described the usefulness of CD203c in identifying the *Aspergillus*-sensitization state when combined with total serum IgE and specific anti-*Aspergillus* IgE [56]. While promising, both TARC and CD203c require further investigation and validation before being accepted into routine clinical practice and recognized as an advance over currently available markers in CF-ABPA.

Episodes of CF-ABPA require corticosteroid therapy, most commonly in the form of prednisolone. This suppresses the allergic and inflammatory response in the airways. Most clinicians commence at 40 mg prednisolone daily for a fortnight followed by a downward titration over three months according to clinical response. Recent evidence has also suggested an alternative approach using pulsed-methylprednisolone at 10-15 mg/kg/day for three days each month for up to ten months yearly [57]. Anti-fungal therapy (in the form of itraconazole) is concurrently administered in this setting although this requires dedicated study and a clearer evidence base. While itraconazole has a better side effect profile, voriconazole or posaconazole are alternative effective agents although the former has been described to have associations with photosensitivity in CF [58]. Other important considerations when using anti-fungal therapy in CF-ABPA is the variable gastrointestinal absorption of itraconazole, key food interactions and emerging azole resistance [59]. Importantly, no randomized controlled trials currently are available to examine the effectiveness of using anti-fungal therapy in CF-ABPA and while anti-IgE

therapy has also been employed particularly in the setting of chronic steroid dependence, the evidence arises only from individual case reports [60, 61].

Importantly and distinctly separate to CF-ABPA, *Aspergillus*-sensitization has an independent and significant clinical effect on lung function and patient morbidity [62]. How a patient evolves into an allergic *Aspergillus*-sensitized state is however uncertain. In most cases, sensitization is unrelated to fungal recovery from sputum and once acquired is linked to declines in pulmonary function and exacerbations [63]. Key risk factors for the *Aspergillus*-sensitized state appear severe CF mutations, baseline FEV₁ > 70%, absence of *Pseudomonas* and prior azithromycin exposure [64]. To address the emerging complexity of *Aspergillus*-associated clinical states in CF, a novel immunologic classification has been proposed. This classification incorporates four parameters: IgE, IgG, sputum galactomannan and PCR detectable *Aspergillus*. Based on a combination of these measures, sub-groups of patients were described including CF-ABPA, *Aspergillus*-sensitized, *Aspergillus* bronchitis and non-diseased. Such classification methodology while aiding clinicians to better phenotype does not account for a large group of patients who persistently recover *Aspergillus* from the airway but do not have sensitization or ABPA [65, 66]. This *Aspergillus*-colonized group has no clinical symptoms and controversy persists over the actual relevance of the fungi within the CF airway. Therefore, distinguishing colonization from infection states is crucial however with the emergence of advanced molecular typing tools such as whole genome sequencing, we may in the near future be able to classify patients based on colonization and/or infection by the same isolate. Where the fungus is detected in over half of all airway specimens from a single patient, the patient is considered to be colonized (non-

ABPA *Aspergillus*-colonization) [3, 66, 67]. Infection is only considered where clinical effects such as abnormalities in lung function, respiratory exacerbations and lack of response to antibiotic treatment occur, however such generalized definitions are subject to significant limitation.

The non-ABPA *Aspergillus*-colonized state is of great interest both clinically and from a research perspective. Whether or not such colonization confers any clinical relevance is a subject of ongoing debate and research. Most early works in the field had varied findings likely explained by the range of definitions used for colonization, differences in study design, duration, recruitment and conduct, particularly in terms of respiratory sampling and fungal isolation protocols used that made data problematic to compare between studies [68-70].

Our group has shown significantly greater radiological abnormalities detected on high resolution computed tomography (HRCT) scanning of the thorax in an *Aspergillus*-colonized cohort versus a non-colonized group. Critically, no difference in lung function was detected indicative that radiology may represent a clearer means of assessing *Aspergillus*-related effects in the absence of CF-ABPA [71]. These data coupled to clinical work illustrating that *Aspergillus* colonization represents a risk factor for hospital admissions in CF provides a strong basis from which one could argue towards potential important clinical effects of *Aspergillus* colonization in the absence of ABPA [72]. Whether eradicating the fungi provides any clinical benefit was the subject of an important study conducted by our group [66].

Our prospective observational study used itraconazole (400 mg/day for 6 weeks) as an eradication regimen to a non-ABPA, steroid naïve *Aspergillus*-colonized CF

population. We illustrated a significant reduction in *Aspergillus* burden in the airways measured both by colony forming unit (CFU) counts and molecular biology. Unexpectedly, anti-fungal treatment attenuated mosaic pattern perfusion on HRCT imaging with no effects on pulmonary function while reducing exacerbation rates and improving quality of life patient scores [66]. Several studies including ours suggest that molecular detection of *Aspergillus* is more sensitive than mycological culture alone. Sputum galactomannan is produced in the fungi's logarithmic growth phase and therefore represents active and clinically important disease; however it is not *Aspergillus* specific as it is a component of the cell walls in other fungi, e.g. *Malassezia* and *Candida* species [73]. Therefore, where therapeutic efficacy needs to be assessed, a combination of both molecular detection and galactomannan may be most useful [66, 74-76]. Other emerging immune-related markers such as the group of human chitinases (acid mammalian chitinase and chitotriosidase) are being examined for their usefulness in these settings by our group and others [77]. These are enzymes produced by human monocytes and neutrophils in response to chitin exposure, an important component of the fungal cell wall [77].

Extensive work by our group and others has been performed assessing the role of vitamin D in *Aspergillus* infection, its receptor (VDR) and the immune response [66]. Links have been suggested between *Aspergillus*, ABPA and vitamin D pathways. For instance, Kreindler *et al.* [78] illustrated that vitamin D₃ treatment attenuated Th2 responses to *Aspergillus* by CD4⁺ T-cells obtained from patients with CF-ABPA. Mice deficient in the vitamin D receptor (VDR) do not develop allergic asthma and have elevated Th2 cytokines IL-5 and IL-13 [79]. Furthering these works are data assessing the

OX40 ligand (OX40L) a co-stimulatory molecule involved in the Th2 response. Vitamin D administration in animal models of CF-ABPA demonstrates that VDR binding to the promoter region of OX40L alters NF- κ B-p50 subunit binding, consequently suppressing both inflammatory and allergic Th2-induced responses [80].

We furthered this work by showing that *Aspergillus* down-regulates VDR expression both at a gene and protein level in airway epithelium and were able to reproduce such findings *in-vivo*. This down-regulation was driven by an immunoevasive *Aspergillus* virulence factor gliotoxin [7, 66]. Reduced gliotoxin and Th2 cytokine (IL-5 and IL-13) levels were identified post-fungal eradication with concurrent reciprocally increased VDR airway receptor expression [66]. Despite our promising results, a double-blind placebo controlled Canadian trial failed to detect any benefit in lung function parameters following itraconazole use [81]. 35 patients in the trial were randomized to either oral itraconazole (5 mg/kg/day) or placebo and followed to 24 weeks. Importantly, detailed analysis of both studies illustrates key differences between them, important when interpreting their findings. Both studies had small patient populations and detected no differences in lung function post-treatment. However the Canadian trial failed to achieve therapeutic itraconazole levels in a significant number of patients, making their results challenging to interpret. Additionally, the Canadian investigators did not utilize molecular detection techniques for *Aspergillus* or radiological endpoints for clinical correlation, both assessments with positive outcomes in our Irish study [81]. Clearly, a need now exists for a well conducted and adequately powered multi-centre trial to determine whether any clinical benefit can be conferred in anti-fungal use for the non-ABPA *Aspergillus*-colonized state.

Risk factors for the development of CF-ABPA include low body mass index, tendency toward atopy, fungal sensitization, azithromycin use and pet ownership [55, 69, 82].

In addition to CF-ABPA, *Aspergillus*-sensitization and *Aspergillus*-colonization, the occurrence of aspergilloma and invasive *Aspergillus*-related disease is more rarely observed in CF, but are manifestations for the clinician to be aware of. Aspergilloma is an aggregation of consolidated hyphae within a pre-existing lung cavity [3]. Aspergilloma can occur in any existing thoracic cavity and is detected predominantly in the upper pulmonary zones by either chest radiography (CXR) or computed tomography (CT) [83]. Most patients are asymptomatic although haemoptysis may occur if the fungus invades into bronchial arteries. Aspergilloma has no association to CF-ABPA. The only intervention required is surgical resection or arterial embolization in the event of persistent or life-threatening bleeds [84, 85]. In selected inoperable cases, CT-guided instillation of anti-fungal therapy (*e.g.* amphotericin-B) shows promise in therapeutic outcomes, however data are currently limited for this in CF patients [86].

Invasive *Aspergillus* disease can be either local (spread into bronchial epithelium) or systemic (spread into the bloodstream). Local spread is referred to as invasive pulmonary aspergillosis (IPA) and is observed at higher frequency than systemic spread termed invasive aspergillosis (IA). Both states are rare in the context of CF, however whether IPA or IA occurs in the setting of CF is largely determined by the acquired genotype of *Aspergillus* and its associated propensity for pathogenicity [87, 88]. In general, angio-invasion of *Aspergillus* is associated with an increased mortality [89]. Pre-transplant identification of airway *Aspergillus* and positive intra-operative *Aspergillus* culture

quadruples risks of developing IA post-operatively, an important consideration in CF patients [90]. Challenges in diagnosing IPA or IA in CF are comparable to that observed in non-CF settings with radiology and galactomannan lacking sensitivity and serology being non-specific [91]. Voriconazole is first line treatment while liposomal amphotericin-B is an alternative agent. Prolonged therapy is required in most cases and serum drug level monitoring is necessary as systemic absorption of anti-fungals is widely variable between individuals [16, 92, 93].

***ASPERGILLUS* SPECIES IN NON-CYSTIC FIBROSIS BRONCHIECTASIS**

Aspergillus-related pathology in non-CF bronchiectasis is thought to be secondary to the entrapment of conidia in respiratory secretions, and their accumulation in the lower airway due to impaired mucociliary clearance. Subsequent germination leads to the formation of hyphae, antigenically active forms of *Aspergillus* that trigger Th2-mediated responses in susceptible patients [29]. Only very rarely does *Aspergillus* display invasive phenotypes in such patients (Table 1). The causal relationship between fungi and respiratory pathology remains uncertain, however it is likely that *Aspergillus* colonization represents the primary factor triggering the development of bronchiectasis or alternatively arises as a consequence and late complication of bronchiectasis from an unrelated origin.

There are two major challenges to understanding the occurrence and role of *Aspergillus* species in non-CF bronchiectasis. Firstly, most published patient series do not consistently report results of mycological investigation and identification. Most airway fungal-related pathology is attributed to *A. fumigatus* largely based on serological surveys. Fungal cultures, which importantly are not always performed in most patients,

inherently have well known limitations including lack of sensitivity with yields highly dependent on the microbiological protocols used and available expertise for the identification of fungal isolates [12, 94, 95]. Secondly, although *Aspergillus*-related pulmonary pathology has been addressed or, at least mentioned, in several reviews and case series focused on well known causes of bronchiectasis, no specific reports on the epidemiology of moulds causing or complicating non-CF bronchiectasis have been published until recently [15]. Considerable variation has been described in the recovery of *Aspergillus* species from sputum cultures of non-CF bronchiectasis, with rates ranging from 6.9% to 24.2% [15, 96].

Most currently available knowledge with regard to *Aspergillus*-associated pathology in non-CF bronchiectasis is related to *A. fumigatus*, a highly prevalent *Aspergillus* species in ambient air [4] and also a frequent coloniser of the lower airway [94]. Its virulence mechanisms and associated factors have been revised elsewhere and are out of the scope of this article [7, 97, 98], however, such factors confer significant pathogenic advantages to the fungus as it is implicated frequently in human pathology. *Aspergillus fumigatus* has been associated with bronchiectasis in severe asthma, ABPA and the recently classified diverse forms of chronic pulmonary aspergillosis (CPA) [99, 100]. *Aspergillus fumigatus* is linked to a 2.01-fold (CI 95% 1.26-3.22) increase in the risk of developing bronchiectasis in sensitized asthmatic patients [101], in whom bronchiectasis is diagnosed in up to two-thirds of cases [101, 102].

ABPA is likely the most frequent *Aspergillus*-related pathology observed in non-CF bronchiectasis cohorts. The burden of ABPA in asthmatic patients is estimated at 2.5% but can range from 0.7% to 3.5% [103]. *Aspergillus fumigatus* has also been

implicated in sensitization and ABPA in up to 10% of patients with idiopathic bronchiectasis [104]. Precise mechanisms that underly the association between *A. fumigatus* sensitization, ABPA and bronchiectasis remains unknown but is likely related to airway remodelling secondary to a progressive allergic inflammation driven by the continuous exposure to *Aspergillus* where it is colonizing the airway.

Interestingly, non CF-bronchiectasis is recognised as a predisposing factor for the development of *A. fumigatus* bronchitis and CPA, as are a number of described aetiologies leading to bronchiectasis such as mycobacterial infection or COPD [9, 105, 106]. Bronchiectasis and non-tuberculous mycobacteria (NTM) are concurrently diagnosed in up to one third of cases of non-CF bronchiectasis. However no causal or interdependent relationship has been established. After excluding ABPA, both bronchiectasis and NTM are strongly associated with the development of CPA [107, 108]. Even more striking is that up to 83.3% of *Mycobacterium avium* complex-associated bronchiectasis are reported to have developed culture-proven CPA, with systemic corticosteroid use a significant risk factor for such co-infection [109]. It is most likely that the development of bronchiectasis-related chronic forms of pulmonary aspergillosis relies on an imbalance between subtly impaired host immunity and *Aspergillus* virulence as described immune defects such as mannose binding lectin (MBL) polymorphisms have been identified [110].

Non-*fumigatus Aspergillus* species are far less commonly found both as colonizers and causative agents of respiratory disease in patients with non-CF bronchiectasis, however species distribution appears to geographically vary between

countries, with a high prevalence of *Aspergillus niger* and *Aspergillus terreus* reported in Japan while *Aspergillus flavus* is dominating in China and India [94, 106, 111, 112].

Aspergillus niger is deemed to be the second commonest *Aspergillus* species complex isolated from non-CF bronchiectasis patients ; however, apart from its allergenic potential, little is known about its precise pathogenicity [15, 113, 114]. *Aspergillus tubingensis* has been recently reported to be frequently associated with acute respiratory exacerbations in a series of non-CF bronchiectatic patients. One such patient is described as having CT findings compatible with aspergillosis whereas the other had *A. tubingensis* isolated concurrently with *A. fumigatus* and *A. flavus* [114]. In our own center experience, non-CF bronchiectasis is the underlying condition found in 52.6% (20/38 cases) of patients diagnosed with CPA following the criteria proposed by Denning and colleagues [115]. *Aspergillus* strains belonging to the Nigri section were the second most common *Aspergillus* sub-group in CPA patients after *A. fumigatus*, and, of interest, were only found in cases where patients had underlying non-CF bronchiectasis (4/20 patients) [116]. Little is known about factors contributing to virulence for species of the *Nigri* section with glycosidases (i.e β -xylosidase, glucoamylase, and 3-phytase B) identified as allergens [117] and phospholipase activity deemed important in invasive disease [118].

Aspergillus terreus is implicated in approximately 10% of ABPA cases in Japan based predominantly on isolation in sputum samples but without serological confirmation. Older reports further support the role of this species complex in the aetiology of selected cases of ABPA [119-121]. The species has rarely been related to other forms of fungal disease in non CF-bronchiectasis, suggestive of low pathogenic potential in the non-immunosuppressed host [122]. In addition, scant information is

accessible about its virulence and associated factors mostly restricted to poorly defined mycotoxins[123], secondary metabolites such as acetylaranotin and hemolysins [124] that may act as potential modulators of thrombotic activity [125].

Aspergillus nidulans and its related species while linked to ABPA are regarded an infrequent cause of bronchiectasis and are rarely described in non-CF bronchiectasis [126-128]. Interestingly, such species present a characteristic association with chronic granulomatous disease (CGD), an infrequent cause of non-CF bronchiectasis [129]. In CGD patients, *A. nidulans* illustrates a particularly aggressive phenotype related to the innate defect in NADPH-oxidase with a strong tendency to cause difficult-to-control IA [130].

THE MYCOBIOME AND FUTURE RESEARCH DIRECTIONS

While progress has been made in understanding the bacterial microbiome in bronchiectasis, study of fungi and associated mycobiome has lagged behind. High rates of *Aspergillus*-associated colonization and disease are now known to occur in a variety of chronic inflammatory respiratory diseases such as asthma [30], COPD and CF [9] and, while the roles of fungi in these disease states are beginning to be understood and the clinical importance of fungi recognized, the theoretical and potentially severe consequences in bronchiectasis now warrant investigations.

There are several reasons for the need to investigate the lung ‘mycobiome’ in patients with bronchiectasis. First, the respiratory tract represents the main portal of entry for inhaled fungal spores [30, 131] and second, fungal respiratory disease, particularly in the context of anatomically abnormal airways, such as that in bronchiectasis has already

been established to contribute to more severe phenotypes in a number of chronic respiratory diseases such as asthma, COPD and CF. In this latter context, our group and others have established that the presence of fungi in the respiratory tract is associated with poorer clinical outcomes [56, 66, 67, 132].

Numerous questions persist regarding *Aspergillus* species in the bronchiectatic lung: when and how do we best assess for it? When are they significant clinically? Do they require treatment? These are just a few of the many uncertainties that face clinicians caring for patients with bronchiectasis and their associated complex microbiological state.

Much remains to be understood with regard to the relationship between *Aspergillus* species and bronchiectasis pathogenesis as they can clearly be involved as both a cause and consequence of the disease. *Aspergillus* can act as the sole cause of bronchiectasis, an opportunistic colonizer of the affected airway or directly infect a patient with existing bronchiectasis. Whether these scenarios are distinct or represent different phases of a continuum whose progression is modulated by the host response is currently unknown.

Very little is known about the natural history of *Aspergillus*-related pathology and how it evolves from a colonization to sensitization to invasive state and how fungi and host immunity interact during such transitions. Although extensive work has been performed with respect to *A. fumigatus* virulence factors, it remains to be determined which of them are essential to provoke pathology, particularly in non-immunocompromised states. Further future investigations may reveal that the full spectrum of pathology induced by *Aspergillus* spp. in bronchiectasis may be far more

extensive than ABPA alone and that species other than *A. fumigatus* are involved more frequently than previously considered. Recent advances in molecular taxonomy will also aid future work, in defining the real distribution of *Aspergillus* species in both CF and non-CF bronchiectasis states.

The complex relationship between bacterial, viral and fungal components of the airway microbiota remain incompletely understood, with “normal” and “pathological” microbiota-related states still to be clearly defined. While promising results have been obtained in early work focused on the CF airway, non-CF related bronchiectasis requires dedicated study. Novel, cheaper and more powerful sequencing techniques thought to improve our knowledge of the human microbiome in both healthy and diseased states may provide the much needed comprehensive panorama of the dynamics, crosstalk and temporal-spatial distribution of bacteria, virus and fungi in the respiratory tract. Once delineated, host factors influencing such dynamics of microbiota will be more easily integrated into the overall picture and it will be possible to elucidate which are the most suitable pathways to be modified for therapeutic benefit.

CONCLUSION

While increasing attention is now focused on *Aspergillus*-associated disease states and the organisms detection in both CF and non-CF bronchiectasis, much remains to be done. An improved understanding of the fungi’s pathogenesis is clearly required to improve the current available diagnostics and to provide targets for therapeutic intervention in appropriate patients. The cross-sectional nature of most available data in the current literature makes it challenging to establish cause and effect clearly. Prospective

controlled studies with treatment arms are an important requirement for the field to progress. However the most complex question that requires addressing is what the actual clinical significance of the fungi detected in bronchiectasis is and whether eradication needs consideration. It is presumed that the true answer likely lies depending on the fungi, clinical status of the patient and the individual's underlying state of immunity.

Many ongoing uncertainties persist in the field including the precise pathogenicity of the isolated fungi and their associated mechanisms, as well as a clear delineation of the spectrum spanning colonization-sensitization and ABPA and therapeutic approaches required particularly in asymptomatic patients. Future work should address these issues but also embrace the emerging clinical and complex phenotypes such as *Aspergillus* bronchitis, particularly in non-immunocompromised individuals [105]. An understanding of these newer phenotypes will allow an identification of sub-groups of fungal 'colonizers' that have been previously ignored or unrecognized, but who may be at risk of clinical deterioration. Continuing to improve our understanding between host factors such as the the immune system in conjunction with disease severity, effects of inflammation and fungal burden will allow us to better determine an individual's susceptibility to an *Aspergillus*-associated disease in bronchiectasis. Both host and *Aspergillus*-related factors are critical in determining if an individual patient will develop a particular disease at a particular point in time. Considering this, we should now anticipate developing strategies to routinely detect and consider treatment where required.

REFERENCES

1. Guinea J, Pelaez T, Alcala L, Bouza E. Outdoor environmental levels of *Aspergillus* spp. conidia over a wide geographical area. *Med Mycol.* 2006;44:349–56.
2. Beffa T, Staib F, Lott Fischer J, *et al.* Mycological control and surveillance of biological waste and compost. *Med Mycol.* 1998;36 Suppl 1:137–45.
3. Chotirmall SH, Al-Alawi M, Mirkovic B, *et al.* *Aspergillus*-associated airway disease, inflammation, and the innate immune response. *Biomed Rese Int.* 2013;2013:723129.
4. Alshareef F, Robson GD. Prevalence, persistence, and phenotypic variation of *Aspergillus fumigatus* in the outdoor environment in Manchester, UK, over a 2-year period. *Med Mycol.* 2014;52:367–75.
5. Abdalla MH. Prevalence of airborne *Aspergillus flavus* in Khartoum (Sudan) airspora with reference to dusty weather and inoculum survival in simulated summer conditions. *Mycopathologia.* 1988;104:137–41.
6. Chotirmall SH, McElvaney NG. Fungi in the cystic fibrosis lung: bystanders or pathogens? *Int J Biochem Cell Biol.* 2014;52:161–73.
7. Chotirmall SH, Mirkovic B, Lavelle GM, McElvaney NG. Immuno-evasive *Aspergillus* virulence factors. *Mycopathologia.* 2014;178:363–70.
8. Murray MA, Chotirmall SH. The impact of immunosenescence on pulmonary disease. *Mediators Inflamm.* 2015;2015:692546.
9. Kosmidis C, Denning DW. The clinical spectrum of pulmonary aspergillosis. *Thorax.* 2015;70:270–7.

10. Delsuc C, Cottureau A, Fréalle E, *et al.* Putative invasive pulmonary aspergillosis in critically ill patients with chronic obstructive pulmonary disease: a matched cohort study. *Crit Care*. 2015;19:421.
11. Agarwal K, Gaur SN, Chowdhary A. The role of fungal sensitisation in clinical presentation in patients with chronic obstructive pulmonary disease. *Mycoses*. 2015;58:531–5.
12. Pashley CH. Fungal culture and sensitisation in asthma, cystic fibrosis and chronic obstructive pulmonary disorder: what does it tell us? *Mycopathologia*. 2014;178:457–63.
13. Huerta A, Soler N, Esperatti M, *et al.* Importance of *Aspergillus* spp. isolation in acute exacerbations of severe COPD: prevalence, factors and follow-up: the FUNGI-COPD study. *Respir Res*. 2014;15:17.
14. Bafadhel M, McKenna S, Agbetile J, *et al.* *Aspergillus fumigatus* during stable state and exacerbations of COPD. *Eur Respir J*. 2014;43:64–71.
15. Maiz L, Vendrell M, Oliveira C, *et al.* Prevalence and factors associated with isolation of *Aspergillus* and *Candida* from sputum in patients with non-cystic fibrosis bronchiectasis. *Respiration*. 2015;89:396–403.
16. Walsh TJ, Anaissie EJ, Denning DW, *et al.* Treatment of aspergillosis: clinical practice guidelines of the Infectious Diseases Society of America. *Clin Infect Dis*. 2008;46:327–60.
17. Cole P. The damaging role of bacteria in chronic lung infection. *J Antimicrob Chemother*. 1997;40 Suppl A:5–10.

18. Cole PJ. Inflammation: a two-edged sword--the model of bronchiectasis. *Eur J Respir Dis Suppl.* 1986;147:6–15.
19. Bilton D, Jones AL. Bronchiectasis: epidemiology and causes. *Eur Respir Mon.* 2011;52:1–10.
20. Shoemark A, Ozerovitch L, Wilson R. Aetiology in adult patients with bronchiectasis. *Respir Med.* 2007;101:1163–70.
21. McShane PJ, Naureckas ET, Streck ME. Bronchiectasis in a diverse US population: effects of ethnicity on etiology and sputum culture. *Chest.* 2012;142:159–67.
22. Foweraker JE, Wat D. Microbiology of non-CF bronchiectasis. *Eur Respir Mon.* 2011;52:68–96.
23. Ciofu O, Hansen CR, Hoiby N. Respiratory bacterial infections in cystic fibrosis. *Curr Opin Pulm Med.* 2013;19:251–8.
24. Martiniano SL, Nick JA. Nontuberculous mycobacterial infections in cystic fibrosis. *Clin Chest Med.* 2015;36:101–15.
25. Parkins MD, Floto RA. Emerging bacterial pathogens and changing concepts of bacterial pathogenesis in cystic fibrosis. *J Cyst Fibros.* 2015;14:293–304.
26. Green H, Jones AM. The microbiome and emerging pathogens in cystic fibrosis and non-cystic fibrosis bronchiectasis. *Semin Respir Crit Care Med.* 2015;36:225–35.
27. King PT, Holdsworth SR, Freezer NJ, Villanueva E, Holmes PW. Microbiologic follow-up study in adult bronchiectasis. *Respir Med.* 2007;101:1633–8.
28. Angrill J, Agusti C, de Celis R, *et al.* Bacterial colonisation in patients with bronchiectasis: microbiological pattern and risk factors. *Thorax.* 2002;57:15–9.

29. Moss RB. Fungi in cystic fibrosis and non-cystic fibrosis bronchiectasis. *Semin Respir Crit Care Med.* 2015;36:207–16.
30. Denning DW, Pashley C, Hartl D, *et al.* Fungal allergy in asthma-state of the art and research needs. *Clin Transl Allergy.* 2014;4:14.
31. Nguyen LD, Viscogliosi E, Delhaes L. The lung mycobiome: an emerging field of the human respiratory microbiome. *Front Microbiol.* 2015;6:89.
32. Borman AM, Palmer MD, Delhaes L, *et al.* Lack of standardization in the procedures for mycological examination of sputum samples from CF patients: a possible cause for variations in the prevalence of filamentous fungi. *Med Mycol.* 2010;48 Suppl 1:S88–97.
33. Horre R, Symoens F, Delhaes L, Bouchara JP. Fungal respiratory infections in cystic fibrosis: a growing problem. *Med Mycol.* 2010;48 Suppl 1:S1–3.
34. Ghannoum MA, Jurevic RJ, Mukherjee PK, *et al.* Characterization of the oral fungal microbiome (mycobiome) in healthy individuals. *PLoS Pathog.* 2010;6(1):e1000713.
35. Hilty M, Burke C, Pedro H, *et al.* Disordered microbial communities in asthmatic airways. *PloS One.* 2010;5(1):e8578.
36. Mounier J, Gouello A, Keravec M, *et al.* Use of denaturing high-performance liquid chromatography (DHPLC) to characterize the bacterial and fungal airway microbiota of cystic fibrosis patients. *J Microbiol.* 2014;52:307–14.
37. Moss RB. Treatment options in severe fungal asthma and allergic bronchopulmonary aspergillosis. *Eur Respir J.* 2014;43:1487–500.

38. Simonin-Le Jeune K, Le Jeune A, Jouneau S, *et al.* Impaired functions of macrophage from cystic fibrosis patients: CD11b, TLR-5 decrease and sCD14, inflammatory cytokines increase. *PLoS One*. 2013;8:e75667.
39. Leveque M, Simonin-Le Jeune K, Jouneau S, *et al.* Soluble CD14 acts as a DAMP in human macrophages: origin and involvement in inflammatory cytokine/chemokine production. *FASEB J*. 2017;31:1891–1902.
40. Chaudhary N, Datta K, Askin FB, Staab JF, Marr KA. Cystic fibrosis transmembrane conductance regulator regulates epithelial cell response to *Aspergillus* and resultant pulmonary inflammation. *Am J Respir Crit Care Med*. 2012;185:301–10.
41. Hartl D, Latzin P, Zissel G, *et al.* Chemokines indicate allergic bronchopulmonary aspergillosis in patients with cystic fibrosis. *Am J Respir Crit Care Med*. 2006;173:1370–6.
42. Chauhan B, Santiago L, Hutcheson PS, *et al.* Evidence for the involvement of two different MHC class II regions in susceptibility or protection in allergic bronchopulmonary aspergillosis. *J Allergy Clin Immunol*. 2000;106:723–9.
43. Miller PW, Hamosh A, Macek M, Jr., *et al.* Cystic fibrosis transmembrane conductance regulator (CFTR) gene mutations in allergic bronchopulmonary aspergillosis. *Am J Hum Genet*. 1996;59:45–51.
44. Pihet M, Carrère J, Cimon B, *et al.* Occurrence and relevance of filamentous fungi in respiratory secretions of patients with cystic fibrosis--a review. *Med Mycol*. 2009;47:387–97.

45. Chotirmall SH, Branagan P, Gunaratnam C, McElvaney NG. *Aspergillus*/allergic bronchopulmonary aspergillosis in an Irish cystic fibrosis population: a diagnostically challenging entity. *Respir Care*. 2008;53:1035–41.
46. Stevens DA, Moss RB, Kurup VP, *et al*. Allergic bronchopulmonary aspergillosis in cystic fibrosis--state of the art: Cystic Fibrosis Foundation Consensus Conference. *Clin Infect Dis*. 2003;37 Suppl 3:S225–64.
47. Delhaes L, Frealle E, Pinel C. Serum markers for allergic bronchopulmonary aspergillosis in cystic fibrosis: State of the art and further challenges. *Med Mycol*. 2010;48 Suppl 1:S77–87.
48. Casaulta C, Fluckiger S, Cramer R, Blaser K, Schoeni MH. Time course of antibody response to recombinant *Aspergillus fumigatus* antigens in cystic fibrosis with and without ABPA. *Pediatr Allergy Immunol*. 2005;16:217–25.
49. de Oliveira E, Giavina-Bianchi P, Fonseca LA, Franca AT, Kalil J. Allergic bronchopulmonary aspergillosis' diagnosis remains a challenge. *Respir Med*. 2007;101:2352–7.
50. Kurup VP, Kumar A. Immunodiagnosis of aspergillosis. *Clin Microbiol Rev*. 1991;4:439–56.
51. Kurup VP. *Aspergillus* antigens: which are important? *Med Mycol*. 2005;43 Suppl 1:S189–96.
52. Hutcheson PS, Knutsen AP, Rejent AJ, Slavin RG. A 12-year longitudinal study of *Aspergillus* sensitivity in patients with cystic fibrosis. *Chest*. 1996;110:363–6.
53. Latzin P, Hartl D, Regamey N, *et al*. Comparison of serum markers for allergic bronchopulmonary aspergillosis in cystic fibrosis. *Eur Respir J*. 2008;31:36–42.

54. Gernez Y, Dunn CE, Everson C, *et al.* Blood basophils from cystic fibrosis patients with allergic bronchopulmonary aspergillosis are primed and hyper-responsive to stimulation by *aspergillus* allergens. *J Cyst Fibros.* 2012;11:502–10.
55. Gernez Y, Walters J, Mirkovic B, *et al.* Blood basophil activation is a reliable biomarker of allergic bronchopulmonary aspergillosis in cystic fibrosis. *Eur Respir J.* 2016;47:177–85.
56. Mirković B, Lavelle GM, Azim AA, *et al.* The basophil surface marker CD203c identifies *Aspergillus* sensitization in cystic fibrosis. *J Allergy Clin Immunol.* 2016;137:436–43.e9.
57. Cohen-Cymberknoh M, Blau H, Shoseyov D, *et al.* Intravenous monthly pulse methylprednisolone treatment for ABPA in patients with cystic fibrosis. *J Cyst Fibros.* 2009;8:253–7.
58. Rondeau S, Couderc L, Dominique S, *et al.* High frequency of voriconazole-related phototoxicity in cystic fibrosis patients. *Eur Respir J.* 2012;39:782–4.
59. Burgel PR, Baixench MT, Amsellem M, *et al.* High prevalence of azole-resistant *Aspergillus fumigatus* in adults with cystic fibrosis exposed to itraconazole. *Antimicrob Agents Chemother.* 2012;56:869–74.
60. Elphick HE, Southern KW. Antifungal therapies for allergic bronchopulmonary aspergillosis in people with cystic fibrosis. *Cochrane Database Syst Rev.* 2012;6:CD002204.
61. Tanou K, Zintzaras E, Kaditis AG. Omalizumab therapy for allergic bronchopulmonary aspergillosis in children with cystic fibrosis: A synthesis of published evidence. *Pediatr Pulmonol.* 2014;49:503–7.

62. Fillaux J, Bremont F, Murriss M, *et al.* Assessment of *Aspergillus* sensitization or persistent carriage as a factor in lung function impairment in cystic fibrosis patients. *Scand J Infect Dis.* 2012;44:842–7.
63. Baxter CG, Moore CB, Jones AM, Webb AK, Denning DW. IgE-mediated immune responses and airway detection of *Aspergillus* and *Candida* in adult cystic fibrosis. *Chest.* 2013;143:1351–7.
64. Fillaux J, Bremont F, Murriss M, *et al.* *Aspergillus* sensitization or carriage in cystic fibrosis patients. *Pediatr Infect Dis J.* 2014;33:680–6.
65. Baxter CG, Dunn G, Jones AM, *et al.* Novel immunologic classification of aspergillosis in adult cystic fibrosis. *J Allergy Clin Immunol.* 2013;132:560–6.e10.
66. Coughlan CA, Chotirmall SH, Renwick J, *et al.* The effect of *Aspergillus fumigatus* infection on vitamin D receptor expression in cystic fibrosis. *Am J Respir Crit Care Med.* 2012;186:999–1007.
67. Chotirmall SH, O'Donoghue E, Bennett K, *et al.* Sputum *Candida albicans* presages FEV(1) decline and hospital-treated exacerbations in cystic fibrosis. *Chest.* 2010;138:1186–95.
68. Bargon J, Dauletbaev N, Kohler B, *et al.* Prophylactic antibiotic therapy is associated with an increased prevalence of *Aspergillus* colonization in adult cystic fibrosis patients. *Respir Med.* 1999;93:835–8.
69. Jubin V, Ranque S, Stremmler Le Bel N, Sarles J, Dubus JC. Risk factors for *Aspergillus* colonization and allergic bronchopulmonary aspergillosis in children with cystic fibrosis. *Pediatr Pulmonol.* 2010;45:764–71.

70. de Vrankrijker AM, van der Ent CK, van Berkhout FT, *et al.* *Aspergillus fumigatus* colonization in cystic fibrosis: implications for lung function? *Clinical Microbiol Infect.* 2011;17:1381–6.
71. McMahon MA, Chotirmall SH, McCullagh B, *et al.* Radiological abnormalities associated with *Aspergillus* colonization in a cystic fibrosis population. *Eur J Radiol.* 2012;81:e197–202.
72. Amin R, Dupuis A, Aaron SD, Ratjen F. The effect of chronic infection with *Aspergillus fumigatus* on lung function and hospitalization in patients with cystic fibrosis. *Chest.* 2010;137:171–6.
73. Barnes RA. Early diagnosis of fungal infection in immunocompromised patients. *J Antimicrob Chemother.* 2008;61 Suppl 1:i3–6.
74. Baxter CG, Rautemaa R, Jones AM, *et al.* Intravenous antibiotics reduce the presence of *Aspergillus* in adult cystic fibrosis sputum. *Thorax.* 2013;68:652–7.
75. Loussert C, Schmitt C, Prevost MC, *et al.* *In vivo* biofilm composition of *Aspergillus fumigatus*. *Cell Microbiol.* 2010;12:405–10.
76. Hope WW, Petraitis V, Petraitiene R, *et al.* The initial 96 hours of invasive pulmonary aspergillosis: histopathology, comparative kinetics of galactomannan and (1->3) beta-D-glucan and consequences of delayed antifungal therapy. *Antimicrob Agents Chemother.* 2010;54:4879–86.
77. Hector A, Chotirmall SH, Lavelle GM, *et al.* Chitinase activation in patients with fungus-associated cystic fibrosis lung disease. *J Allergy Clin Immunol.* 2016;138:1183–89.e4.

78. Kreindler JL, Steele C, Nguyen N, *et al.* Vitamin D3 attenuates Th2 responses to *Aspergillus fumigatus* mounted by CD4+ T cells from cystic fibrosis patients with allergic bronchopulmonary aspergillosis. *J Clin Invest.* 2010;120:3242–54.
79. Wittke A, Weaver V, Mahon BD, August A, Cantorna MT. Vitamin D receptor-deficient mice fail to develop experimental allergic asthma. *J Immunol.* 2004;173:3432–6.
80. Nguyen NL, Chen K, McAleer J, Kolls JK. Vitamin D regulation of OX40 ligand in immune responses to *Aspergillus fumigatus*. *Infect Immun.* 2013;81:1510–9.
81. Aaron SD, Vandemheen KL, Freitag A, *et al.* Treatment of *Aspergillus fumigatus* in patients with cystic fibrosis: a randomized, placebo-controlled pilot study. *PLoS One.* 2012;7(4):e36077.
82. Thronicke A, Heger N, Antweiler E, *et al.* Allergic bronchopulmonary aspergillosis is associated with pet ownership in cystic fibrosis. *Pediatr Allergy Immunol.* 2016;27:597-603.
83. Abramson S. The air crescent sign. *Radiology.* 2001;218:230–2.
84. Akbari JG, Varma PK, Neema PK, Menon MU, Neelakandhan KS. Clinical profile and surgical outcome for pulmonary aspergilloma: a single center experience. *Ann Thorac Surg.* 2005;80:1067–72.
85. Swanson KL, Johnson CM, Prakash UB, *et al.* Bronchial artery embolization : experience with 54 patients. *Chest.* 2002;121:789–95.
86. Giron J, Poey C, Fajadet P, *et al.* CT-guided percutaneous treatment of inoperable pulmonary aspergillomas: a study of 40 cases. *Eur J Radiol.* 1998;28:235–42.

87. Gibson PG. Allergic bronchopulmonary aspergillosis. *Semin Respir Crit Care Med*. 2006;27:185–91.
88. Kauffman HF. Immunopathogenesis of allergic bronchopulmonary aspergillosis and airway remodeling. *Front Biosci*. 2003;8:e190–6.
89. Fukuda T, Boeckh M, Carter RA, *et al*. Risks and outcomes of invasive fungal infections in recipients of allogeneic hematopoietic stem cell transplants after nonmyeloablative conditioning. *Blood*. 2003;102:827–33.
90. Luong ML, Chaparro C, Stephenson A, *et al*. Pretransplant *Aspergillus* colonization of cystic fibrosis patients and the incidence of post-lung transplant invasive aspergillosis. *Transplantation*. 2014;97:351–7.
91. Warren TA, Yau Y, Ratjen F, Tullis E, Waters V. Serum galactomannan in cystic fibrosis patients colonized with *Aspergillus* species. *Med Mycol*. 2012;50:658–60.
92. Limper AH, Knox KS, Sarosi GA, *et al*. An official American Thoracic Society statement: Treatment of fungal infections in adult pulmonary and critical care patients. *Am J Respir Crit Care Med*. 2011;183:96–128.
93. Herbrecht R, Denning DW, Patterson TF, *et al*. Voriconazole versus amphotericin B for primary therapy of invasive aspergillosis. *N Engl J Med*. 2002;347:408–15.
94. Mortensen KL, Johansen HK, Fursted K, *et al*. A prospective survey of *Aspergillus* spp. in respiratory tract samples: prevalence, clinical impact and antifungal susceptibility. *Eur J Clin Microbiol Infect Dis*. 2011;30:1355–63.
95. Pashley CH, Fairs A, Morley JP, *et al*. Routine processing procedures for isolating filamentous fungi from respiratory sputum samples may underestimate fungal prevalence. *Med Mycol*. 2012;50:433–8.

96. Qi Q, Wang W, Li T, Zhang Y, Li Y. Aetiology and clinical characteristics of patients with bronchiectasis in a Chinese Han population: A prospective study. *Respirology*. 2015;20:917–24.
97. McCormick A, Loeffler J, Ebel F. *Aspergillus fumigatus*: contours of an opportunistic human pathogen. *Cell Microbiol*. 2010;12:1535–43.
98. Abad A, Fernandez-Molina JV, Bikandi J, *et al*. What makes *Aspergillus fumigatus* a successful pathogen? Genes and molecules involved in invasive aspergillosis. *Rev Iberoam Micol*. 2010;27:155–82.
99. Smith NL, Denning DW. Underlying conditions in chronic pulmonary aspergillosis including simple aspergilloma. *Eur Respir J*. 2011;37:865–72.
100. Denning DW, Cadranel J, Beigelman-Aubry C, *et al*. Chronic pulmonary aspergillosis: rationale and clinical guidelines for diagnosis and management. *Eur Respir J*. 2016;47:45–68.
101. Menzies D, Holmes L, McCumesky G, Prys-Picard C, Niven R. *Aspergillus* sensitization is associated with airflow limitation and bronchiectasis in severe asthma. *Allergy*. 2011;66:679–85.
102. Fairs A, Agbetile J, Hargadon B, *et al*. IgE sensitization to *Aspergillus fumigatus* is associated with reduced lung function in asthma. *Am J Respir Crit Care Med*. 2010;182:1362–8.
103. Denning DW, Pleuvry A, Cole DC. Global burden of allergic bronchopulmonary aspergillosis with asthma and its complication chronic pulmonary aspergillosis in adults. *Med Mycol*. 2013;51:361–70.

104. Bahous J, Malo JL, Paquin R, *et al.* Allergic bronchopulmonary aspergillosis and sensitization to *Aspergillus fumigatus* in chronic bronchiectasis in adults. *Clin Allergy*. 1985;15:571–9.
105. Chrdle A, Mustakim S, Bright-Thomas RJ, *et al.* *Aspergillus* bronchitis without significant immunocompromise. *Ann N Y Acad Sci*. 2012;1272:73–85.
106. Tashiro T, Izumikawa K, Tashiro M, *et al.* Diagnostic significance of *Aspergillus* species isolated from respiratory samples in an adult pneumology ward. *Med Mycol*. 2011;49:581–7.
107. Bonaiti G, Pesci A, Marruchella A, *et al.* Nontuberculous mycobacteria in noncystic fibrosis bronchiectasis. *Biomed Res Int*. 2015;2015:197950.
108. Kunst H, Wickremasinghe M, Wells A, Wilson R. Nontuberculous mycobacterial disease and *Aspergillus*-related lung disease in bronchiectasis. *Eur Respir J*. 2006;28:352–7.
109. Fujita K, Ito Y, Hirai T, *et al.* Prevalence and risk factors for chronic co-infection in pulmonary *Mycobacterium avium* complex disease. *BMJ Open Respir Res*. 2014;1(1):e000050.
110. Harrison E, Singh A, Morris J, *et al.* Mannose-binding lectin genotype and serum levels in patients with chronic and allergic pulmonary aspergillosis. *Int J Immunogenet*. 2012;39:224–32.
111. Chu CM, Woo PC, Chong KT, *et al.* Association of presence of *Aspergillus* antibodies with hemoptysis in patients with old tuberculosis or bronchiectasis but no radiologically visible mycetoma. *J Clin Microbiol*. 2004;42:665–9.

112. Chakrabarti A, Sethi S, Raman DS, Behera D. Eight-year study of allergic bronchopulmonary aspergillosis in an Indian teaching hospital. *Mycoses*. 2002;45:295–9.
113. Ishiguro T, Takayanagi N, Kagiya N, *et al*. Clinical characteristics of biopsy-proven allergic bronchopulmonary mycosis: variety in causative fungi and laboratory findings. *Intern Med*. 2014;53:1407–11.
114. Gautier M, Normand AC, L'Ollivier C, *et al*. *Aspergillus tubingensis*: a major filamentous fungus found in the airways of patients with lung disease. *Med mycology*. 2016;54:459–70.
115. Denning DW, Riniotis K, Dobrashian R, Sambatakou H. Chronic cavitary and fibrosing pulmonary and pleural aspergillosis: case series, proposed nomenclature change, and review. *Clin Infect Dis*. 2003;37 Suppl 3:S265–80.
116. Aguilar-Company J, Ruiz-Camps I, Martín-Gómez MT, *et al*. Características epidemiológicas, clínicas diagnósticas y evolutivas de los pacientes con Aspergilosis pulmonar crónica (APC). Congress of the Spanish Society for Clinical Microbiology and Infectious Diseases (SEIMC); Barcelona, Spain, 2016.
117. Denning DW, O'Driscoll BR, Hogaboam CM, Bowyer P, Niven RM. The link between fungi and severe asthma: a summary of the evidence. *Eur Respir J*. 2006;27:615–26.
118. Alp S, Arıkan S. Investigation of extracellular elastase, acid proteinase and phospholipase activities as putative virulence factors in clinical isolates of *Aspergillus* species. *J Basic Microbiol*. 2008;48:331–7.

119. Nakahara Y, Katoh O, Yamada H, Sumida I, Hanada M. Allergic bronchopulmonary aspergillosis caused by *Aspergillus terreus* presenting lobar collapse. Intern Med. 1992;31:140–2.
120. Laham MN, Allen RC, Greene JC. Allergic bronchopulmonary aspergillosis (ABPA) caused by *Aspergillus terreus*: specific lymphocyte sensitization and antigen-directed serum opsonic activity. Ann Allergy. 1981;46:74–80.
121. Laham MN, Carpenter JL. *Aspergillus terreus*, a pathogen capable of causing infective endocarditis, Pulmonary mycetoma, and allergic bronchopulmonary aspergillosis. Am Rev Respir Dis. 1982;125:769–72.
122. Ng J, Ho S, Krishnan P, Teoh SC. *Aspergillus terreus* endogenous endophthalmitis in a nonimmunocompromised patient with a history of bronchiectasis. Ocul Immunol Inflamm. 2013;21:231–3.
123. Pugliese A, Savarino A, Vidotto V, Cantamessa C, Pescarmona GP. Effect of *Aspergillus terreus* mycotoxins on nitric oxide synthase activity in human erythroid K-562 cells. Cell Biochem Funct. 1999;17:35–45.
124. Nayak AP, Blachere FM, Hettick JM, *et al.* Characterization of recombinant terrelysin, a hemolysin of *Aspergillus terreus*. Mycopathologia. 2011;171:23–34.
125. Speth C, Blum G, Hagleitner M, *et al.* Virulence and thrombocyte affectation of two *Aspergillus terreus* isolates differing in amphotericin B susceptibility. Med Microbiol Immunol. 2013;202:379–89.
126. Tillie-Leblond I, Tonnel AB. Allergic bronchopulmonary aspergillosis. Allergy. 2005;60:1004–13.

127. Kontoyiannis DP, Marr KA, Park BJ, *et al.* Prospective surveillance for invasive fungal infections in hematopoietic stem cell transplant recipients, 2001-2006: overview of the Transplant-Associated Infection Surveillance Network (TRANSNET) Database. *Clin Infect Dis.* 2010;50:1091–100.
128. Burgos A, Zaoutis TE, Dvorak CC, *et al.* Pediatric invasive aspergillosis: a multicenter retrospective analysis of 139 contemporary cases. *Pediatrics.* 2008;121:e1286–94.
129. Henriët SS, Verweij PE, Warris A. *Aspergillus nidulans* and chronic granulomatous disease: a unique host-pathogen interaction. *J Infect Dis.* 2012;206:1128–37.
130. Blumental S, Mouy R, Mahlaoui N, *et al.* Invasive mold infections in chronic granulomatous disease: a 25-year retrospective survey. *Clin Infect Dis.* 2011;53:e159–69.
131. Pashley CH, Fairs A, Free RC, Wardlaw AJ. DNA analysis of outdoor air reveals a high degree of fungal diversity, temporal variability, and genera not seen by spore morphology. *Fungal Biol.* 2012;116:214–24.
132. McMahon MA, Chotirmall SH, McCullagh B, *et al.* Radiological abnormalities associated with *Aspergillus* colonization in a cystic fibrosis population. *Eur J Radiol.* 2012;81:e197–202.

FIGURE LEGEND

Figure 1: Spectrum of clinical disease associated with *A. fumigatus*.

CPA: Chronic pulmonary aspergillosis; ABPA: Allergic bronchopulmonary aspergillosis;

ABPM: Allergic bronchopulmonary mycosis; SAFS: Severe asthma with fungal sensitization.

Table 1: Summary of the common *Aspergillus*-associated disease states observed in CF and non-CF related bronchiectasis

BRONCHIECTASIS	
<i>Cystic fibrosis related</i>	<i>Non-cystic fibrosis related</i>
Allergic bronchopulmonary aspergillosis (ABPA)	
<i>Aspergillus</i> -sensitization	
Non-ABPA <i>Aspergillus</i> -colonization	
Aspergilloma (rare)	
	Chronic pulmonary aspergillosis (CPA)
Invasive aspergillosis (rare)	

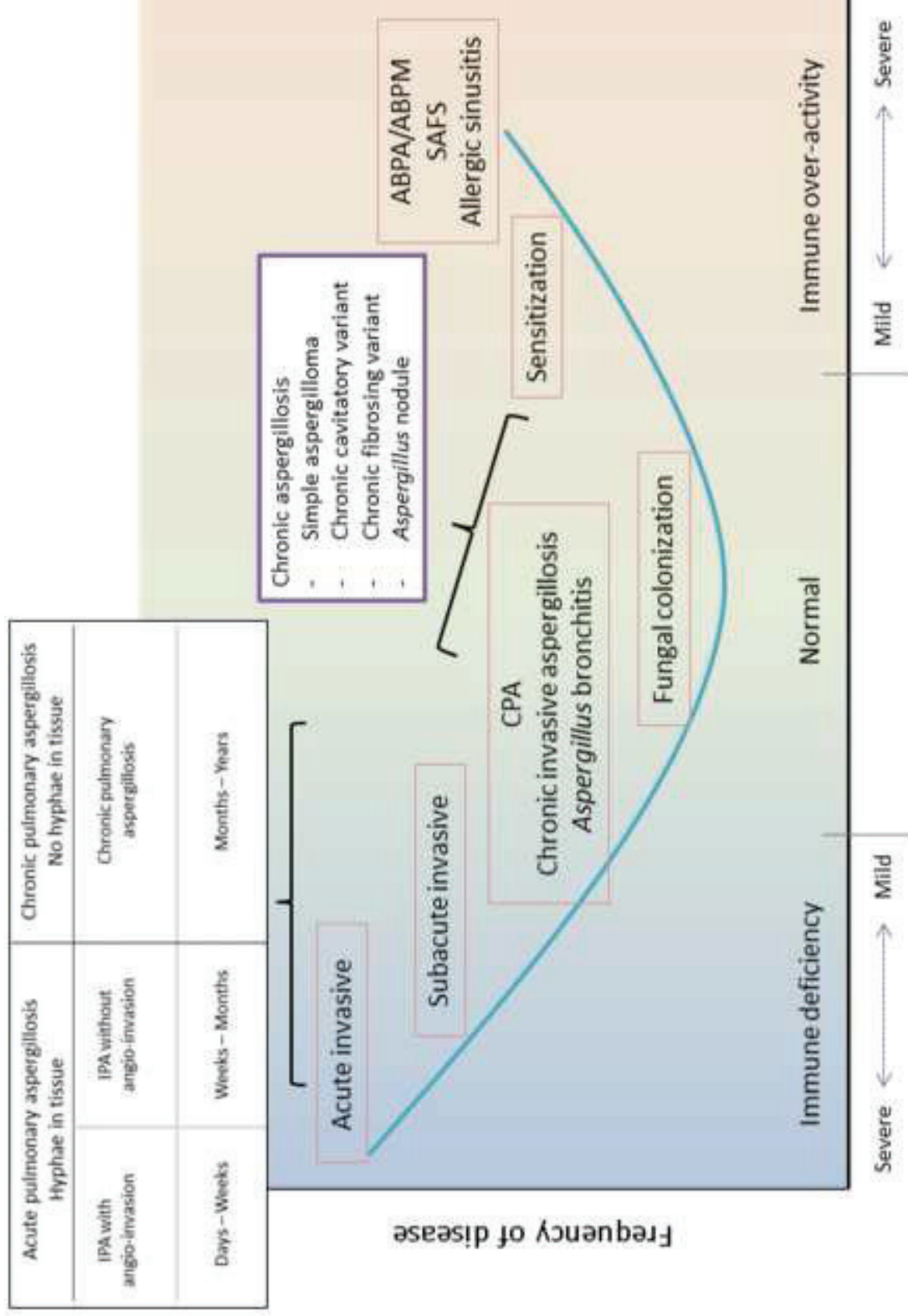


Figure 1