

A Biodegradable, Sustained-Released, Tacrolimus Microfilm Drug Delivery System for the Management of Allergic Conjunctivitis in a Mouse Model

Yu-Chi Liu,¹⁻³ Xu Wen Ng,⁴ Erica Pei Wen Teo,¹ Heng-Pei Ang,¹ Nyein Chan Lwin,¹ Nicole Shu Wen Chan,² Subbu S. Venkatraman,⁴ Tina T. Wong,¹⁻⁴ and Jodhbir S. Mehta^{1-3,5}

¹Singapore Eye Research Institute, Singapore

²Singapore National Eye Centre, Singapore

³Ophthalmology and Visual Sciences Academic Clinical Programme, Duke-NUS Medical School, Singapore

⁴School of Materials Science and Engineering, Nanyang Technological University, Singapore, Singapore

⁵School of Material Science & Engineering and School of Mechanical and Aerospace Engineering, Nanyang Technological University

Correspondence: Jodhbir S. Mehta, Singapore National Eye Centre, 11 Third Hospital Avenue, Singapore 168751;

jodhmehta@gmail.com.

Tina T. Wong, Singapore National Eye Centre, 11 Third Hospital Avenue, Singapore 168751; tina.wong.t.l@sneec.com.sg.

Submitted: September 28, 2017

Accepted: December 31, 2017

Citation: Liu YC, Ng XW, Teo EPW, et al. A biodegradable, sustained-released, tacrolimus microfilm drug delivery system for the management of allergic conjunctivitis in a mouse model. *Invest Ophthalmol Vis Sci*. 2018;59:675-684. <https://doi.org/10.1167/iovs.17-23066>

PURPOSE. To investigate the drug release profiles of a tacrolimus-loaded poly(D,L-lactide-co-ε-caprolactone) (PLC) microfilm, and to evaluate its efficacy on the treatment of allergic conjunctivitis using a mouse model.

METHODS. The in vitro and in vivo drug release profiles were first characterized. Balb/c mice were immunized with short ragweed (SRW) injection followed by re-challenges with topical SRW solution. The mice were divided into six groups ($n = 12$ in each): negative control (NC); positive control (PC); tacrolimus eye drops (Te); subconjunctival tacrolimus microfilm (Tm); dexamethasone eye drops (De); and tacrolimus + dexamethasone eye drops (Te+De). The mice were evaluated for 28 days by a scoring system for allergic conjunctivitis. Histopathologic and immunohistochemical staining with CD11c, CD4, and IL-4 were performed.

RESULTS. The microfilms were biocompatible and delivered clinically sufficient dose in a sustained manner, with a steady rate of 0.212 to 0.243 μg/day in vivo. Compared to the PC groups, the Te, Tm, De, and Te+De groups significantly reduced the allergic clinical scores throughout the study period (all $P < 0.01$; 0.0 ± 0.0 , 5.6 ± 0.9 , 3.3 ± 0.9 , 3.2 ± 0.9 , 1.9 ± 0.4 and 1.7 ± 0.8 for the NC, PC, Tm, Te, De, and Te+De groups, respectively, at 4 weeks after treatment). The suppressed eosinophils, CD11c, CD4, and IL-4 expression were also observed in all treatment groups, with more reduction in the Te+De group.

CONCLUSIONS. Tacrolimus-loaded microfilms display good biocompatibility and desirable sustained drug release. It was as effective as conventional tacrolimus eye drops on the treatment of allergic conjunctivitis, providing a promising clinically applicable alternative for controlling allergic disease activity, or other immune-mediated ocular diseases.

Keywords: allergic conjunctivitis, tacrolimus, drug delivery system

Ocular allergy is one of the most frequent external eye diseases. Allergic disease affects about 25% of the population, while the incidence of allergic conjunctivitis ranges from 5% to 22% of the population.¹ For treatment of allergic conjunctivitis, a variety of medications have been used which include antihistamines, mast-cell stabilizers, and nonsteroidal anti-inflammatory drugs. Topical corticosteroids are effective therapy for ocular allergy and are the mainstay therapy for moderate to severe allergic conjunctivitis or when conservative therapy has failed.¹ However, their judicious use is indicated, especially for long-term use, due to their propensity to induce cataract, elevated intraocular pressure, and potential secondary infections.² Immunomodulatory agents (e.g., cyclosporine A) have been therefore used for ocular allergic diseases, such as vernal keratoconjunctivitis or for refractory cases.^{3,4}

Tacrolimus is another immunomodulatory agent, which is similar to cyclosporine A in its functional mechanism, but with about 100-fold higher potency.⁵ It suppresses T-cell activation,

T-helper cell-mediated response, B-cell proliferation, and cytokine release, especially IL-2, IL-4, and IL-5, which play roles in ocular allergic diseases.⁶ Topical tacrolimus eye drops, with the concentrations ranging from 0.005% to 0.1% have been shown to be effective in treating refractory allergic conjunctivitis, severe allergic conjunctivitis, giant papillary conjunctivitis, and vernal keratoconjunctivitis.⁷⁻¹⁰ In a large prospective clinical study involving 1436 patients with refractive allergic ocular diseases, 0.1% tacrolimus eye drops significantly ameliorated allergic signs and symptoms after 1 month of treatment, and about 50% of all patients using topical steroid were weaned off.⁸ Tacrolimus dermatologic ointment with the concentrations of 0.02% to 0.1%, have also been shown to be well-tolerated, safe, and effective treatment for atopic conjunctivitis and atopic blepharitis.^{11,12}

As ocular allergic disease is a chronic condition, long-term use of topical eye drops is necessary. As with any disease that requires long-term medication for management, adequate, and



TABLE. Clinical Scoring of Experimental Allergic Conjunctivitis

	0	1	2	3
Conjunctival redness	Absent	Mild	Moderate	Severe
Chemosis	Absent	Mild and deep fornix base	Moderate and deep fornix base	Severe and shallow fornix base
Lid edema	Absent	Mild	Moderate	Severe
Tearing	Normal	Mild projection	Moderate projection	Tearing

effective treatment of allergic eye disease is dependent on patient compliance. In addition, topical eye drops have a short duration of action and a poor bioavailability of less than 10%, resulting in the need for frequent application to achieve an adequate therapeutic level.¹³ Several drug delivery platforms have been developed and investigated to overcome the abovementioned challenges, and these include liposomal formulation, microspheres, nanoparticle delivery, and polymeric implants.^{14,15} Our previous work has shown that subconjunctival poly [d,l-lactide-co-e-caprolactone] (PLC) microfilms were biodegradable and displayed good biocompatibility and feasibility.¹⁶ We further loaded the PLC microfilms with prednisolone acetate (PA) and demonstrated that the PA microfilms significantly reduced corneal graft rejection after corneal transplantation,¹⁷ reduced postoperative inflammation and prolonged bleb survival following glaucoma filtering surgery,¹⁸ and suppressed the severity of uveitis in animal models.¹⁹ We have also loaded the PLC microfilms with timolol maleate and demonstrated the sustained intraocular pressure-lowering effects.²⁰

In the present study, we aimed to evaluate the efficacy of the biodegradable, tacrolimus-loaded PLC drug delivery system on allergic conjunctivitis using a mouse model. We also compared the effects of the tacrolimus-loaded microfilms with those of conventional topical tacrolimus eye drops and topical corticosteroid eye drops.

METHODS

Drug Delivery System Fabrication

Polymeric microfilms were prepared using a solution casting method. Copolymer PLC (d,l-lactide to e-caprolactone molar ratio was 70/30, with intrinsic viscosity of 1.6 dL/g; Purac Far East Pte Ltd, Singapore) and tacrolimus (Sigma-Aldrich Corp., Singapore) with a predetermined drug loading percentage of 3 wt% were dissolved in dichloromethane to form a polymer solution. This drug-polymer mixture was cast on a glass plate using an automatic film applicator. Subsequently, the films were dried under a fume hood for 1 day, followed by drying in a vacuum oven at 37°C. After drying, the microfilms were manually cut into the standard size of 1.6 × 2.0 × 0.8 mm. All the samples were sterilized by ethylene oxide at 37°C prior to implantation.

In Vitro and In Vivo Drug Release Study

For the in vitro drug release study, the tacrolimus-loaded microfilm was weighed before testing, and then immersed in an individual amber vial containing 5 mL PBS. Subsequently, at 1 and 4 days, and at 1 week and weekly thereafter for 8 weeks ($n = 3$ for each time point), the microfilms were taken out, rinsed with deionized water, then dried in a vacuum oven at 37°C over a week. After drying, each microfilm was dissolved fully in 10 mL of acetonitrile, and then the amount of residual drug in each microfilm was determined by high-performance

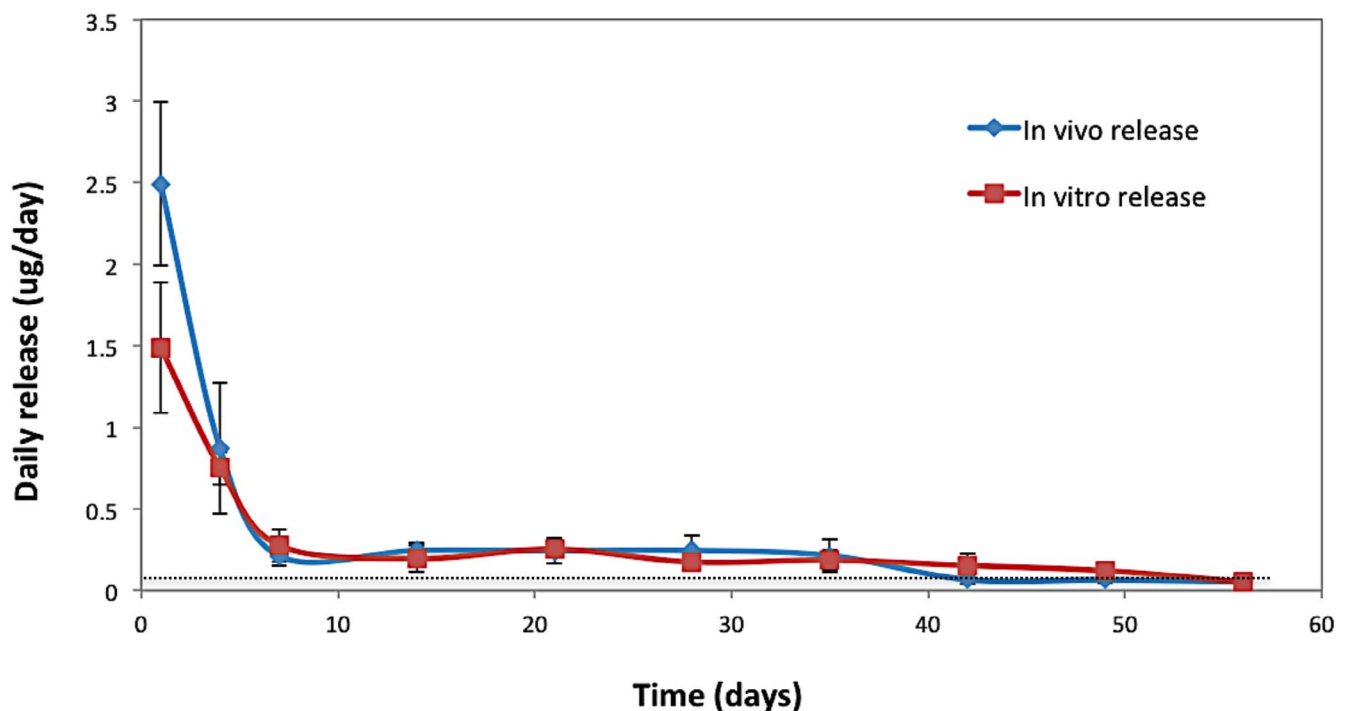


FIGURE 1. A graph showing the daily drug release from the tacrolimus-loaded microfilms in vitro and in vivo. The dotted line indicates the targeted daily release dose.

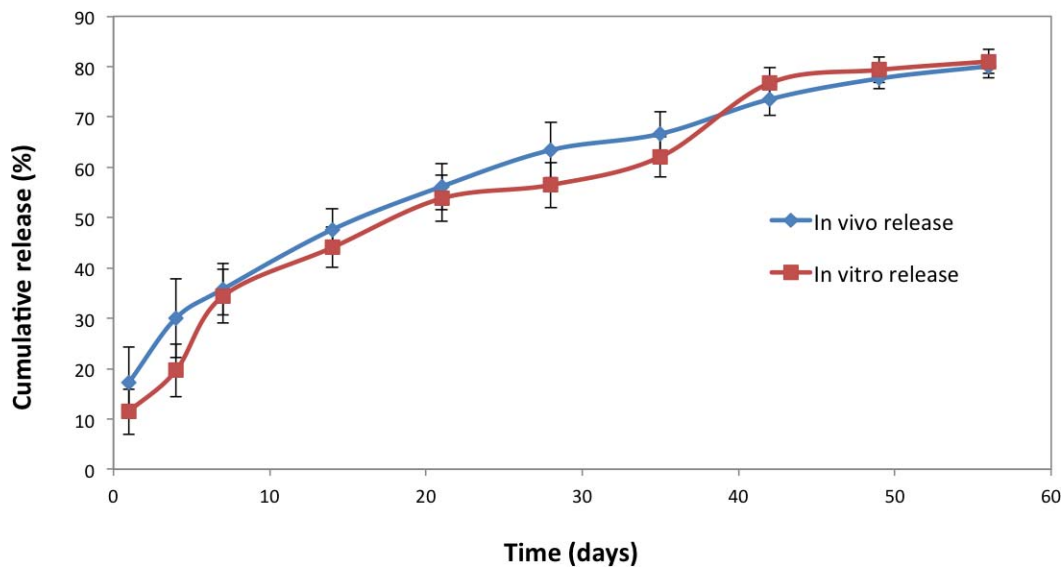


FIGURE 2. A graph showing the cumulative drug release from the tacrolimus-loaded microfilms in vitro and in vivo.

liquid chromatography (HPLC). The amount of drug released was quantified by subtracting the residual drug amount from the initial loading amount, and the daily and cumulative drug release were derived accordingly.

For the in vivo drug release study, we used 30 eyes of 15 male Balb/c mice aged 8 to 12 weeks. All animals were treated in accordance with the tenets of the ARVO Statement for the Use of Animals in Ophthalmic and Vision Research, and the protocol was approved by the Institutional Animal Care and Use Committee of SingHealth. After the animals had been anesthetized with intraperitoneal injection of ketamine hydrochloride (35–50 mg/kg) and xylazil (5–10 mg/kg), a subconjunctival pocket via blunt dissection above the limbus was created with an approximate 2.0-mm incision at the superotemporal aspect, and the microfilm then was inserted into the subconjunctival pocket. Closure with one 10-0 nylon sutures was done to ensure secure implantation of the microfilm. The surgical procedures were performed by the same surgeon (YCL). The microfilms were retrieved at 1 and 4 days, and at 1 week and weekly thereafter for 8 weeks postimplantation. The

daily drug release and cumulative drug release were determined as described above.

Experimental Groups

Another 72 Balb/c mice (144 eyes) were used. Experimental allergic conjunctivitis was induced using previously described methods with modifications.^{21,22} The mice were immunized with 50 μ g short ragweed (SRW) pollen (Bioscience; Cambridge, UK) in 5 mg aluminum hydroxide (Imject; Thermo Fisher Scientific; Pittsburgh, PA, USA) by footpad injection on day 0 and day 5. Allergic conjunctivitis was induced by multiple topical challenges with 1.5 mg SRW suspended in 10 μ L PBS into mice eyes once a day from day 10 to day 38. The mice were randomly allocated to six groups ($n = 12$ mice for each group):

1. Negative control (NC) group: mice were not systemic immunized nor rechallenge with topical SRW.
2. Positive control (PC) group: mice were systemic immunized and rechallenge with topical SRW. Both

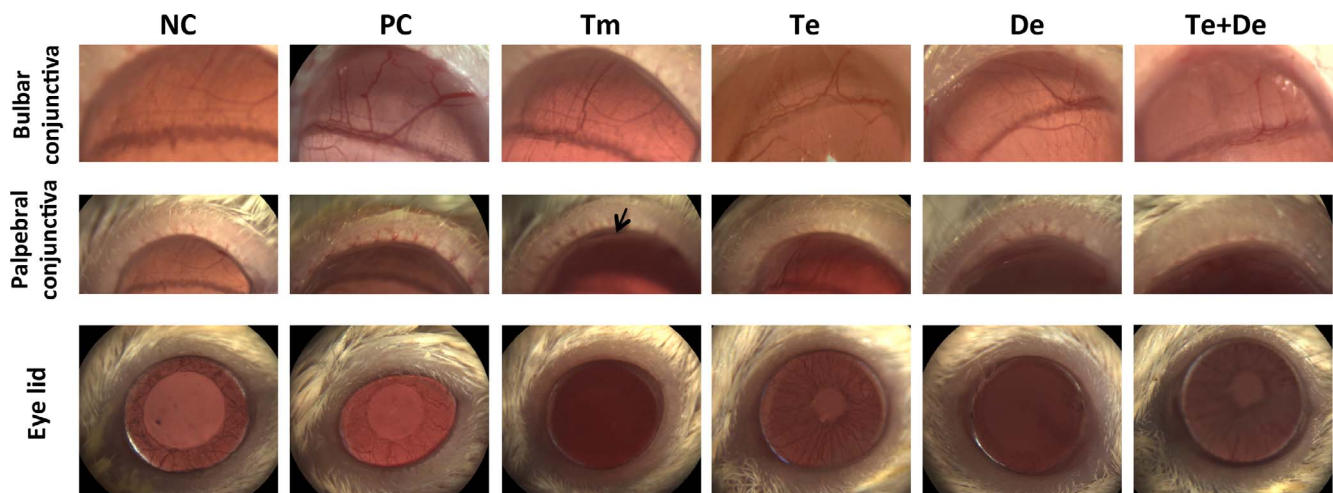


FIGURE 3. Slit lamp biomicroscopy evaluation at day 28 after induction of allergic conjunctivitis for the (A) NC, (B) PC, (C) Tm, (D) Te, (E) De, and (F) Te+De groups. The mice in the PC group had severe lid edema, marked bulbar and palpebral conjunctival vessels, chemosis, and marked tearing, whereas there were less allergic signs in the treatment groups (Tm, Te, De, or Te+De groups). The *arrow* indicated the implanted microfilm.

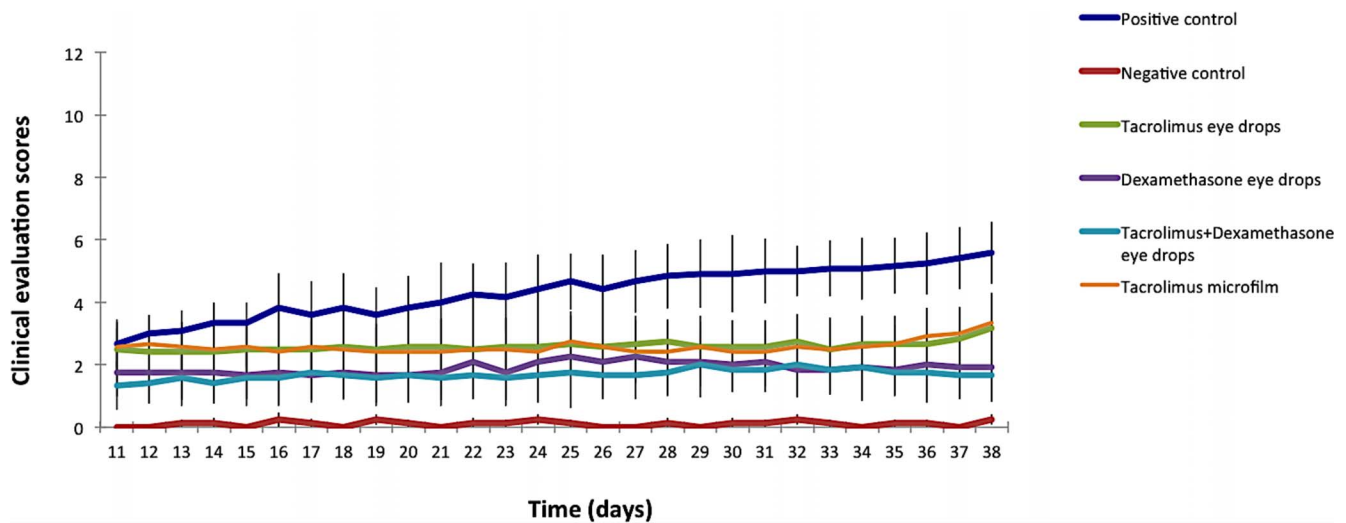


FIGURE 4. Mean clinical scores (0–12) assessing the conjunctival redness (0–3), chemosis (0–3), lid edema (0–3) and tearing (0–3) for different groups at different time points. The treatment groups (Tm, Te, De, or Te+De groups) had significantly lower mean scores compared to the PC group at all the time points (all $P < 0.05$).

eyes received topical normal saline treatment four times a day from day 10 to day 38.

3. Tacrolimus microfilm (Tm) group: mice were systemically immunized and re-challenged with topical SRW. Both eyes received subconjunctival tacrolimus microfilm at day 10, as described above.
4. Tacrolimus eye drops (Te) group: mice were systemically immunized and re-challenged with topical SRW. Both eyes received topical 0.02% tacrolimus eye drops (Leiter's pharmacy) four times a day from day 10 to day 38.
5. Dexamethasone eye drops (De) group: both eyes received topical 0.1% dexamethasone eye drops (Alcon) four times a day from day 10 to day 38, after systemic immunization and topical re-challenges by SRW.
6. Tacrolimus and dexamethasone eye drops (Te+De) group: both eyes received topical 0.1% dexamethasone eye drops and 0.02% tacrolimus eye drops four times a day from day 10 to day 38, after systemic immunization and topical re-challenges by SRW.

Clinical Evaluation

The signs of allergic conjunctivitis were assessed 20 minutes after each topical SRW challenge from day 10 to day 38, using a

modified scoring system by evaluating the conjunctival redness (0–3); chemosis (0–3); lid edema (0–3); and tearing (0–3; total score: 0–12; Table).²³ For the Tm group, the evaluation was done on the area apart from the microfilm insertion site to better reflect the allergic conjunctivitis condition. The microfilm insertion site was also examined weekly using the Hackett-McDonald ocular scoring system²⁴ to assess the conjunctival congestion (0–3); conjunctival swelling (0–3); and conjunctival discharge (0–3) using slit-lamp biomicroscopy. The clinical evaluation was done by a single observer (NCL) who was blinded to the allocation.

Histology Analysis, Picrosirius Red, Giemsa, and Immunohistochemistry Staining

The mice were euthanized by intracardiac injection of overdosed sodium pentobarbitone at week 4. The eyes were enucleated and embedded in an optimal cutting temperature compound (Leica Microsystems, Nussloch, Germany) at -80°C and cryosectioned at 5- μm thick sections. The sections were then processed for hematoxylin and eosin (H&E) histochemistry and Giemsa staining (Sigma Aldrich Corp., St. Louis, MO, USA) and then visualized under light microscopy (Axioplan 2; Carl Zeiss Meditec AG, Oberkochen, Germany). On Giemsa

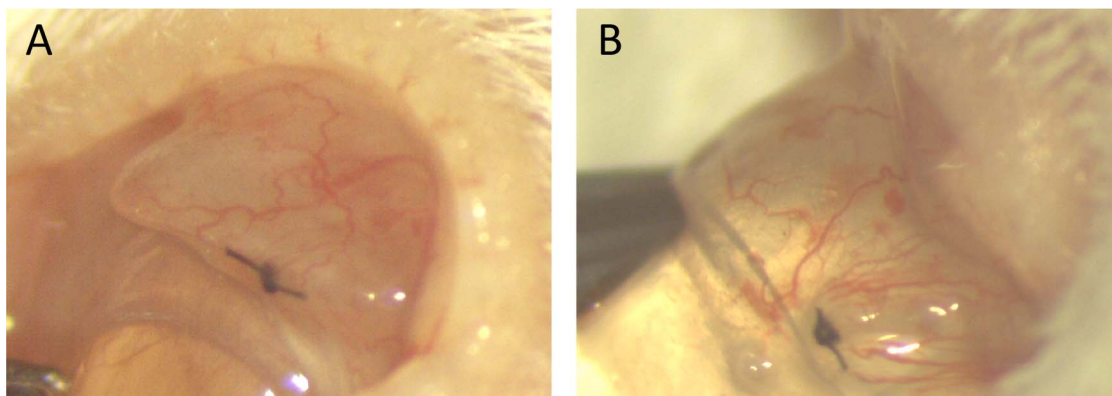


FIGURE 5. Slit lamp photographs showing the microfilm implantation area at day 1 (A) and week 8 after insertion (B). Mild to moderate conjunctival vessels congestion and conjunctival edema were observed around the microfilm at day 1 but resolved with time.

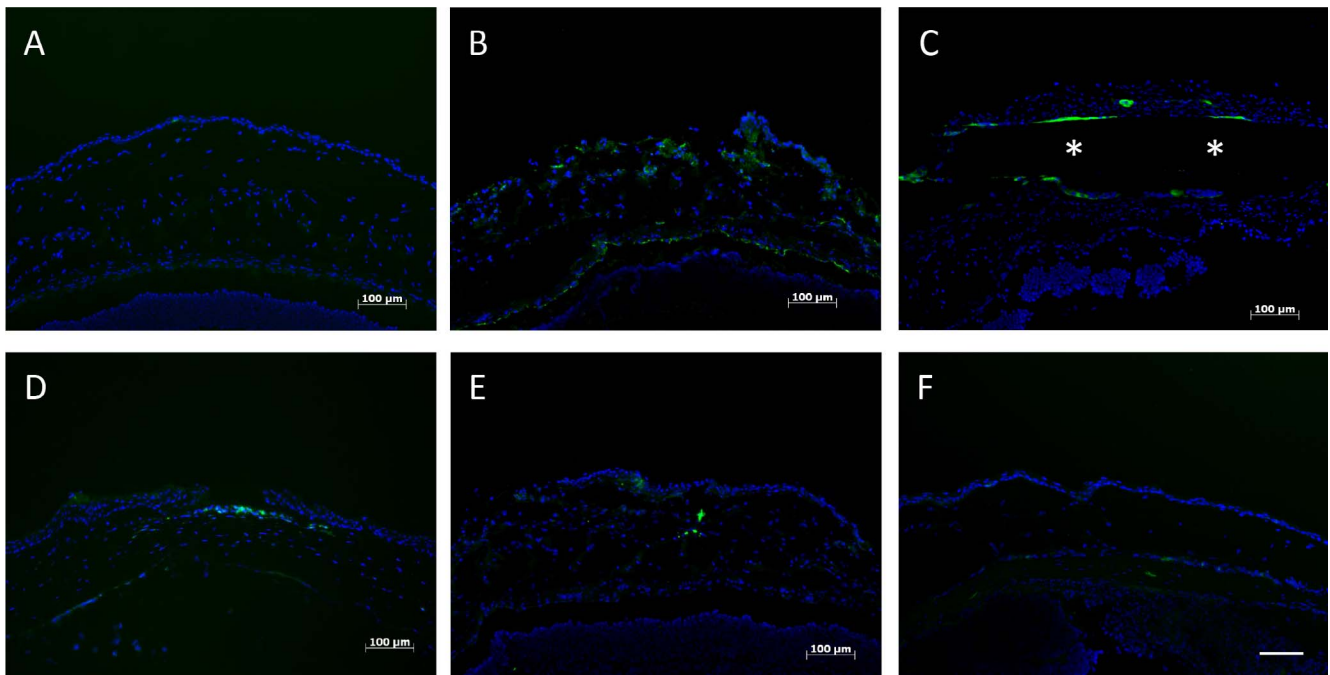


FIGURE 6. Immunohistochemistry staining for CD11c cells at day 28 after induction of allergic conjunctivitis for the (A) NC, (B) PC, (C) Tm, (D) Te, (E) De, and (F) Te+De groups. There was a noticeable reduction of CD11c cells in the Tm and Te groups, and CD11c cells were negligible in the De and Te+De groups. Cell nuclei were stained blue with DAPI, and CD11c-positive cells were stained green. Asterisks indicated the implanted microfilm. Original magnification: $\times 100$, Scale bar: 100 μm .

staining, the number of eosinophils was quantified in three nonoverlapping sections in each conjunctival specimen. The cells were counted in a $\times 100$ microscopic field by a single, masked observer (EP-WT). The sections in the Tm group were also stained with Picrosirius red (Sigma Sirius Red; Sigma

Aldrich Corp., Steinheim, Germany) to determine the amount and extent of collagen encapsulation around the microfilms. For the immunohistochemistry staining, the sections were fixed with freshly prepared 4% neutral buffered paraformaldehyde (Sigma Aldrich Corp.) for 15 minutes, washed and rinsed

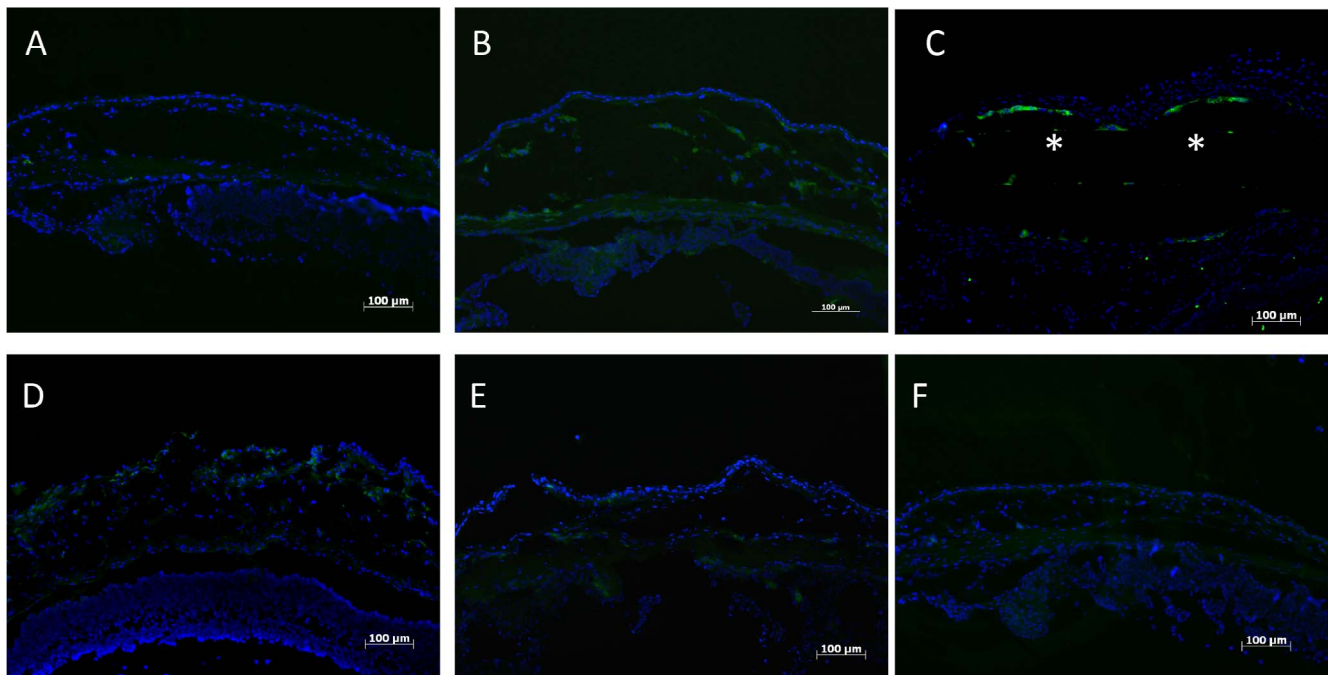


FIGURE 7. Expression of CD4 at day 28 after induction of allergic conjunctivitis for the (A) NC, (B) PC, (C) Tm, (D) Te, (E) De, and (F) Te+De groups. The treatment groups (Tm, Te, De, and Te+De) reduced the expression of CD4 cells, and more reduction was seen in the De and Te+De groups. Cell nuclei were stained blue with DAPI, and CD4-positive cells were stained green. Asterisks indicated the implanted microfilm. Original magnification: $\times 100$. Scale bar: 100 μm .

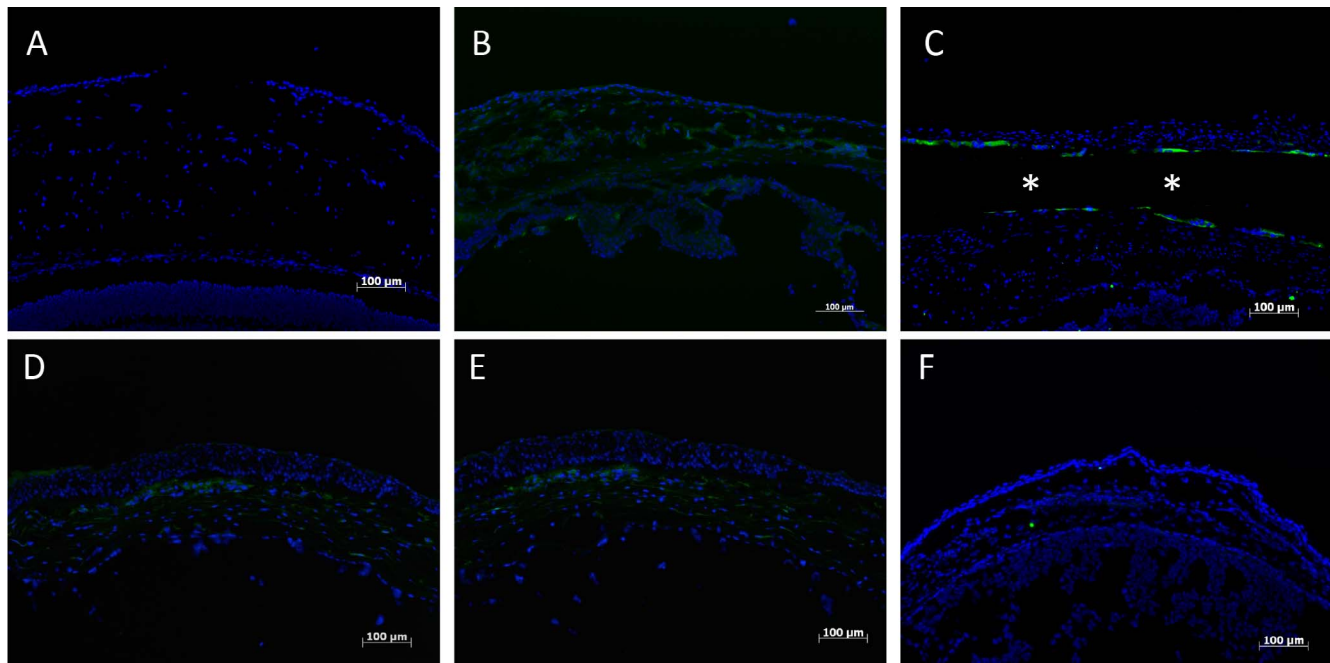


FIGURE 8. Expression of IL-4 at day 28 after induction of allergic conjunctivitis for the (A) NC, (B) PC, (C) Tm, (D) Te, (E) De, and (F) Te+De groups. The suppression of IL-4 expression was observed in the Tm and Te groups, and the suppression was more pronounced in the De and Te+De groups. Cell nuclei were stained blue with DAPI, and IL-4-positive cells were stained green. Asterisks indicated the implanted microfilm. Original magnification: $\times 100$. Scale bar: 100 μm .

with 1X PBS. Permeabilization and blocking of nonspecificities was done by incubation in PBS containing 4% bovine serum albumin (Sigma-Aldrich Corp.) and 0.10% Triton X-100 (Sigma-Aldrich Corp.) for 1 hour. This was followed with primary antibody labeling hamster monoclonal antibody against CD11c (4 mg/mL, BD Pharmingen, Franklin Lakes, NJ, USA); rat monoclonal antibody against CD4 (1.25 mg/mL, BD Pharmingen); and rat monoclonal antibody against IL-4 (2.5 mg/mL, BD Pharmingen), respectively, at 4°C overnight. The secondary antibodies used were goat anti-rat AlexaFluor 488-conjugated (2.6 mg/mL, Life Technologies, Carlsbad, CA, USA) and goat anti-hamster fluorescein isothiocyanate-conjugated (2.5 mg/mL, BioLegend, San Diego, CA, USA). After washes, sections were mounted with medium (UltraCruz Mounting Medium with DAPI; Santa Cruz Biotechnology, Dallas, TX, USA) and viewed under fluorescence microscopy (Carl Zeiss Meditec AG).

Statistical Analysis

All data were expressed as mean \pm SD. Statistical comparisons for the clinical evaluation and eosinophil quantification among different groups were performed using Kruskal-Wallis test with Dunn post-hoc tests. Statistical analyses were performed using commercial software (STATA version 13; StataCorp, College Station, TX, USA). Values of P less than 0.05 were considered statistically significant.

RESULTS

In Vitro and In Vivo Drug Release Profiles

There was an initial burst of 2.493 and 1.487 μg at day 1 in vivo and in vitro, respectively, followed by a steady amount of drug released after week 1. A daily drug release was measured at 0.212 to 0.243 μg and 0.186 to 0.277 μg in vivo and in vitro, respectively (Fig. 1). At day 42, the in vivo daily release was

0.067 μg and decreased gradually thereafter. The cumulative drug release profile revealed that tacrolimus-loaded microfilms achieved a steady, sustained release of drug in vitro and in vivo. At 8 weeks, the microfilms reached 80.09% and 81.02% of drug release in vivo and in vitro, respectively (Fig. 2).

Clinical Evaluation

The mice in the PC group developed severe lid edema, marked congested bulbar and palpebral conjunctival vessels, chemosis, and marked tearing, whereas there were less tearing, lid edema, chemosis, bulbar and palpebral conjunctival hyperemia in the treatment groups (Tm, Te, De, and Te+De groups; Fig. 3). Changes in the mean score of clinical evaluation are shown in Figure 4. At day 38 (i.e., under 4-week treatment after the induction of allergic conjunctivitis), the mean clinical score was 0.3 ± 0.1 , 5.6 ± 1.1 , 3.3 ± 1.1 , 3.2 ± 1.1 , 1.9 ± 1.2 and 1.7 ± 1.0 for the NC, PC, Tm, Te, De, and Te+De groups, respectively. As compared to the PC groups, the treatments significantly reduced the allergic clinical scores at all time points (all $P < 0.001$ for the Tm, Te, De, and Te+De groups, respectively, except that between the PC and Tm group at day 11 [$P = 0.026$], and that between the PC and Te group at day 11 [$P = 0.019$]). There was no significant difference between the Tm and Te groups at all the time points (all $P > 0.05$). The De group had lower scores than the Tm and Te groups at all the time points, but the differences were not significant. The Te+De group had the lowest score among all the treatment groups throughout the study period.

At the tacrolimus-microfilm implantation area, mild degree of conjunctival congestion and conjunctival edema were observed at day 1, with a mean Hackett-McDonald ocular score of 4.0 ± 1.0 . The conjunctival hyperemia and chemosis around the microfilm site resolved gradually with time (Fig. 5), with a Hackett-McDonald ocular score of 3.6 ± 0.8 , 2.7 ± 0.6 , and 2.1 ± 1.2 at week 1, week 4, and week 8 after implantation, respectively.

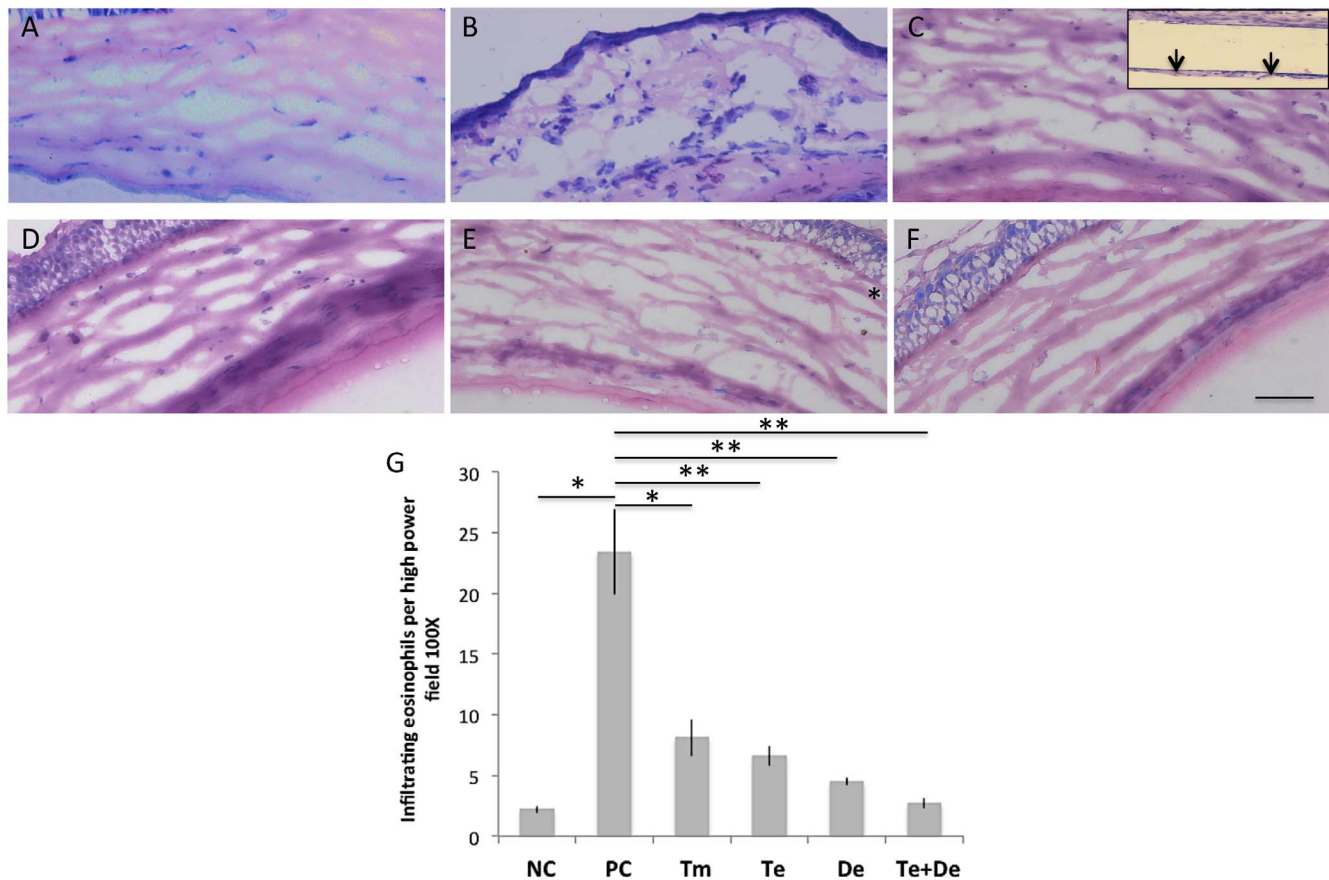


FIGURE 9. Giemsa staining for eosinophils at day 28 after induction of allergic conjunctivitis for the (A) NC, (B) PC, (C) Tm, (D) Te, (E) De, and (F) Te+De groups. The eosinophils infiltration to the subconjunctival space was noticeable in the PC group but negligible in the other groups. Arrows indicated the implanted microfilm. The bar graph showed the quantification of eosinophil infiltrate for different groups. The number of eosinophils was significantly lower in the Te, Tm, De, and Te+De groups than the (G) PC group. Original magnification: $\times 100$. Scale bar: 100 μm . Error bars indicate standard deviation. * $P < 0.05$. ** $P < 0.01$.

Histology Analysis, Picosirius Red, Giemsa, and Immunohistochemistry Staining

At the conclusion of the study, all the conjunctiva in the PC group had significant expression of CD11c (marker for dendritic cells); CD4 (marker for T cells); and IL-4 (pro-allergic cytokine). There was staining of CD11c, CD4, and IL-4 along the margin of microfilm in the Tm group, and suppression of the above marker expression was seen in both Te and Tm groups (Figs. 6–8). Compared to the Te and Tm groups, minimal staining of CD11c, CD4, and IL-4 was observed in the De and Te+De groups. On the Giemsa staining, the eosinophils infiltrating to the subconjunctival space were noticeable in the PC group but there were negligible cells in the other groups (Figs. 9A–F). The number of eosinophils was significantly lower in the Te, Tm, De, and Te+De groups than in the PC group ($P = 0.012$, $P < 0.01$, $P < 0.01$, $P < 0.01$, respectively; Fig. 9G).

Histologic sections with H&E staining revealed that there were no significant inflammatory cells within the subconjunctival space and mild degree of fibrotic capsule formation around the tacrolimus-loaded microfilm 4 weeks after insertion (Fig. 10A). Picosirius red staining for collagen also confirmed the extent of collagen encapsulation of the microfilm. When viewed with a polarized light, a thin layer of mature type I collagen fibers (stained as red or yellow) was observed around the microfilm (Fig. 10B).

DISCUSSION

In our study, we developed a tacrolimus-loaded drug delivery system that has shown good biocompatibility, and prolonged release of tacrolimus to effectively reduce the allergic conjunctivitis reaction in a mouse model for 8 weeks.

Tacrolimus has been loaded to polymeric drug delivery vehicles for ocular use by some researchers.^{25,26} Souza et al.²⁵ reported an intravitreal tacrolimus-loaded poly(D,L-lactide-co-glycolide) (PLGA) implant provided prolonged release of drug up to 6 weeks, and there was no evidence of toxic effects of implants. Sakurai et al.²⁶ also reported a scleral PLGA plug containing tacrolimus was effective in suppressing the inflammation of experimental uveitis in a rabbit model for at least 6 weeks.²⁶ Compared to those designs, the subconjunctival microfilm reported in the present study is more ideal for conjunctival diseases like allergic conjunctivitis, and this is the first described tacrolimus drug delivery system inserted subconjunctivally to our knowledge. A polymeric implant, compared to particle delivery systems (i.e., liposomal formulation, microspheres, and nanoparticle delivery), allows easier removal of the drug delivery system to reverse unwanted side effects. Furthermore, a polymeric implant has the capability of loading more drug in weight, and can be fabricated into various dimensions to modulate the amount and duration of drug release.¹⁵ Instead of using PLGA copolymers, we used PLC copolymers in the present study. PLC copolymers metabolize into lactic acid and caproic acid that eliminate safely via the

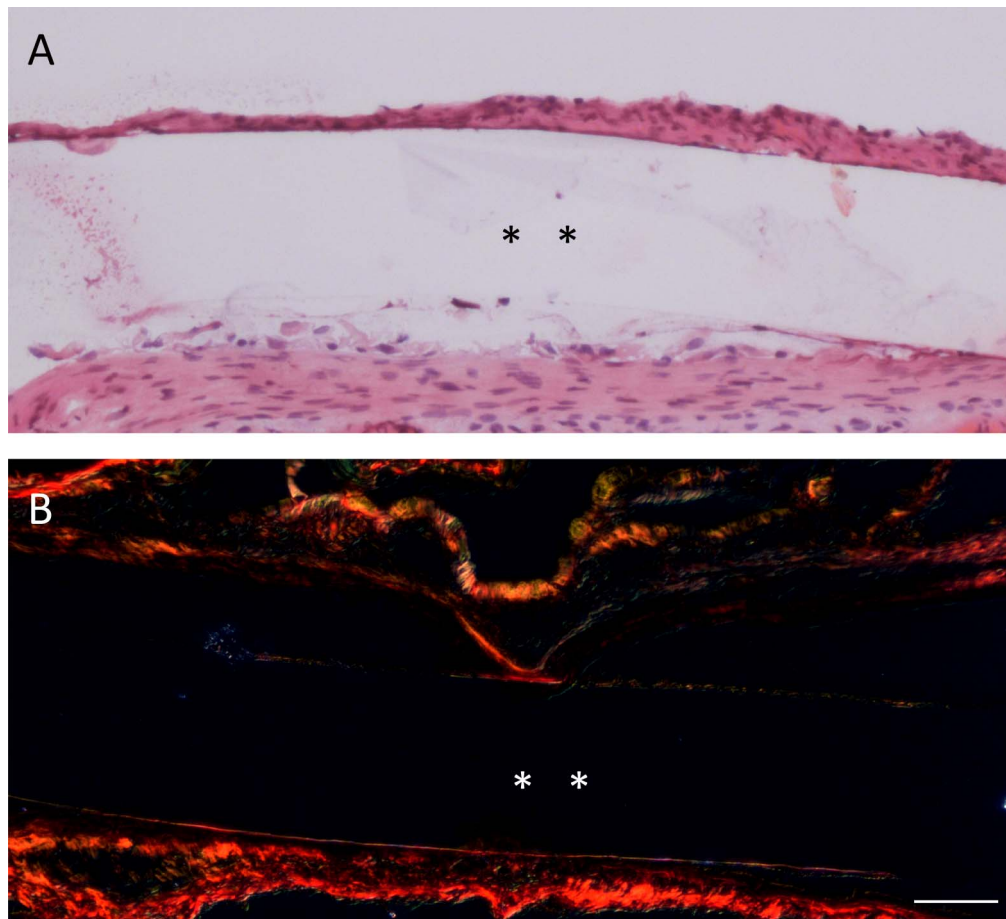


FIGURE 10. Histologic sections with (A) H&E and (B) Picrosirius red collagen staining of tacrolimus-loaded microfilm 4 weeks after insertion. There were very minimal inflammatory cells within the subconjunctival space (A) and a thin layer collagen fibrotic capsule around the implanted microfilm (A, B). Asterisks indicated the implanted microfilm. Original magnification: $\times 200$. Scale bar: 50 μm .

Krebs cycle.²⁷ In comparison with PLGA, PLC is more hydrophobic and has more semicrystalline structure. These characteristics allow PLC to have a slower hydrolysis rate, and therefore achieve a longer release.²⁸ Moreover, PLC copolymers are softer and more elastic, as it has a lower glass transition temperature than PLGA.²⁹ A softer material can minimize the surgical trauma during the implantation procedure as well as the risk of erosion or extrusion of the implant following the insertion.

The concentrations of topical tacrolimus eye drops used in the published clinical studies ranged from 0.005% to 0.1%.⁷⁻¹⁰ In our institute, tacrolimus eye drops are used in 0.02% and four times daily. Taking into account the bioavailability of topical tacrolimus solution is 3%,³⁰ and one drop of tacrolimus solution is 3 μL (the maximum volume for the capacity of the mice conjunctival sac), the target daily drug release of the microfilm was 0.072 μg . Our *in vivo* drug release profiles showed that the tacrolimus microfilm reached and maintained above the daily target dose up to week 6. We have previously shown that the amount of loaded drug is proportional to the size of the microfilms,¹⁶ and the size of the microfilms in the present study was limited to the eyeball of the mice. For future studies and clinical trials, larger microfilms with greater amount of loaded drug will be designed, and the drug concentration in the target tissue (i.e., conjunctiva) will be analyzed. In addition, the major reported adverse reaction of tacrolimus eye drops is ocular burning sensation upon drop instillation (42.9%–81%).^{7,9} This ocular irritation is related to

the eye drops instillation that can be avoided with the use of a sustained drug release system.

It has been shown that CD11c+ immunoreactive cells largely infiltrate the conjunctiva in experimental allergic conjunctivitis models.²² Allergic eye diseases involve a complex immunologic reaction, including immunoglobulin E (IgE)-mediated hypersensitivity and T-lymphocyte-mediated hypersensitivity. Allergen-specific T helper 2 type lymphocytes play important roles in the immuno-pathophysiology of allergic disorders. When allergic inflammation occurs, CD4+ T cells produce proallergic cytokines, including IL-4, IL-5, and IL-13, which subsequently trigger IgE production and eosinophil activation.^{31,32} In our immunochemistry assays, tacrolimus microfilm and tacrolimus eye drops equally suppressed the expression of CD11c, CD4, and IL-4 in the subconjunctival space. The staining alongside the border of the tacrolimus microfilms was thought to result from the tissue response to the implant. In the current study, the last time point was 1 month post-implantation. However, using the same implant, we have previously shown resolution of this inflammatory response by 3 months.¹⁶ Compared to the Te and Tm groups, as expected, the De and Te+De groups demonstrated more inhibitory effects on the expression of CD11c, CD4, and IL-4 after 4 weeks of treatment. Corticosteroids are known to provide dramatic improvement in acute symptoms and signs of ocular allergic diseases.³³ However, their use should be limited and carefully monitored because long-term use of topical corticosteroids may result in unwanted side effects, such as

posterior subcapsular cataracts, secondary infection, and elevated intraocular pressure.² Although immunomodulatory agents, such as tacrolimus, do not demonstrate the rapid onset of action like corticosteroids, they carry fewer ocular risks and are safer for prolonged treatment to control disease activity.^{11,34} Some clinical studies have shown that tacrolimus is an effective treatment and can reduce or replace steroid treatment for refractory or severe allergic conjunctivitis patients.^{7,8,11} The tacrolimus-loaded microfilm may be particularly useful in patients with vernal keratoconjunctivitis, a condition that commonly affects pediatric populations in which steroids-related side effect and compliance to eye drops are usually a major concern. Lastly, since one of the advantages of sustained-released microfilms over eye drops is to eliminate the frequent topical applications, we only included the Te+De group in our study without including the Tm+De group.

In conclusion, this study demonstrated desirable drug release profiles of the tacrolimus-loaded PLC microfilm. It delivered a sustained and clinically sufficient drug level for up to 6 weeks, and significantly reduced allergic immunological reaction and symptoms in a mouse allergic conjunctivitis model. For chronic, severe, sight-threatening allergic eye diseases, such as vernal keratoconjunctivitis or atopic keratoconjunctivitis that require long-term therapy, the tacrolimus microfilm provides a promising alternative to conventional tacrolimus eye drops. The biodegradable tacrolimus microfilm has the capacity to be customized to deliver different release profiles depending on different clinical scenarios. Besides ocular allergic diseases, the microfilm may be also effective in the treatment of other ocular immune-mediated diseases, such as corneal graft rejection, scleritis, or ocular pemphigoid.

Acknowledgments

Supported by the Singapore National Research Foundation under its Translational and Clinical Research (TCR) Programme (NMRC/TCR/1021-SERI/2013) and administered by the Singapore Ministry of Health's National Medical Research Council.

Disclosure: **Y.-C. Liu**, None; **X.W. Ng**, None; **E.P.W. Teo**, None; **H.-P. Ang**, None; **N.C. Lwin**, None; **N.S.W. Chan**, None; **S.S. Venkatraman**, None; **T.T. Wong**, None; **J.S. Mehta**, None

References

- Rothman JS, Raizman MB, Friedlaender MH. Seasonal and perennial allergic conjunctivitis. In: Krachmer JH, ed. *Cornea*. 2nd ed. London, UK; Elsevier Mosby; 2005:661.
- Friedlaender MH. Corticosteroid therapy of ocular inflammation. *Int Ophthalmol Clin*. 1983;23:175-182.
- Erdinest N, Solomon A. Topical immunomodulators in the management of allergic eye diseases. *Curr Opin Allergy Clin Immunol*. 2014;14:457-463.
- Vichyanond P, Kosrirukvongs P. Use of cyclosporine A and tacrolimus in treatment of vernal keratoconjunctivitis. *Curr Allergy Asthma Rep*. 2013;13:308-314.
- Sawada S, Suzuki G, Kawase Y, Takaku F. Novel immunosuppressive agent, FK506. In vitro effects on the cloned T cell activation. *J Immunol*. 1987;139:1797-1803.
- Sakuma S, Higashi Y, Sato N, et al. Tacrolimus suppressed the production of cytokines involved in atopic dermatitis by direct stimulation of human PBMC system. (Comparison with steroids.) *Int Immunopharmacol*. 2001;1:1219-1226.
- Ohashi Y, Ebihara N, Fujishima H, et al. A randomized, placebo-controlled clinical trial of tacrolimus ophthalmic suspension 0.1% in severe allergic conjunctivitis. *J Ocul Pharmacol Ther*. 2010;26:165-174.
- Fukushima A, Ohashi Y, Ebihara N, et al. Therapeutic effects of 0.1% tacrolimus eye drops for refractory allergic ocular diseases with proliferative lesion or corneal involvement. *Br J Ophthalmol*. 2014;98:1023-1027.
- Müller GG, José NK, de Castro RS. Topical tacrolimus 0.03% as sole therapy in vernal keratoconjunctivitis: a randomized double-masked study. *Eye Contact Lens*. 2014;40:79-83.
- Kheirkhah A, Zavareh MK, Farzod F, Mahbod M, Behrouz MJ. Topical 0.005% tacrolimus eye drop for refractory vernal keratoconjunctivitis. *Eye (Lond)*. 2011;25:872-880.
- Al-Amri AM. Long-term follow-up of tacrolimus ointment for treatment of atopic keratoconjunctivitis. *Am J Ophthalmol*. 2014;157:280-286.
- Kiiski V, Remitz A, Reitamo S, Mandelin J, Kari O. Long-term safety of topical pimecrolimus and topical tacrolimus in atopic blepharokeratoconjunctivitis. *JAMA Dermatol*. 2014;150:571-573.
- Gao Y, Sun Y, Ren F, Gao S. PLGA-PEG-PLGA hydrogel for ocular drug delivery of dexamethasone acetate. *Drug Dev Ind Pharm*. 2010;36:1131-1138.
- Liu YC, Wong TT, Mehta JS. Intraocular lens as a drug delivery reservoir. *Curr Opin Ophthalmol*. 2013;24:53-59.
- Joachim Loo SC, Jason Tan WL, Khoa SM, et al. Hydrolytic degradation characteristics of irradiated multi-layered PLGA films. *Int J Pharm*. 2008;360:228-230.
- Liu YC, Peng Y, Lwin NC, et al. Optimization of subconjunctival biodegradable microfilms for sustained drug delivery to the anterior segment in a small animal model. *Invest Ophthalmol Vis Sci*. 2013;54:2607-2615.
- Liu YC, Peng Y, Lwin NC, Venkatraman SS, Wong TT, Mehta JS. A biodegradable, sustained-released, prednisolone acetate microfilm drug delivery system effectively prolongs corneal allograft survival in the rat keratoplasty model. *PLoS One*. 2013;8:e70419.
- Ang M, Yan P, Zhen M, et al. Evaluation of sustained release of PLC-loaded prednisolone acetate microfilm on postoperative inflammation in an experimental model of glaucoma filtration surgery. *Curr Eye Res*. 2011;36:1123-1128.
- Ang M, Ng X, Wong C, et al. Evaluation of a prednisolone acetate-loaded subconjunctival implant for the treatment of recurrent uveitis in a rabbit model. *PLoS One*. 2014;9:e97555.
- Ng XW, Liu KL, Veluchamy AB, Lwin NC, Wong TT, Venkatraman SS. A biodegradable ocular implant for long-term suppression of intraocular pressure. *Drug Deliv Transl Res*. 2015;5:469-479.
- Stern ME, Siemasko K, Gao J, et al. Role of interferon-gamma in a mouse model of allergic conjunctivitis. *Invest Ophthalmol Vis Sci*. 2005;46:3239-3246.
- Zheng X, Ma P, de Paiva CS, et al. TSLP and downstream molecules in experimental mouse allergic conjunctivitis. *Invest Ophthalmol Vis Sci*. 2010;51:3076-3082.
- Nakamura T, Toda M, Ohbayashi M, Ono SJ. Detailed criteria for the assessment of clinical symptoms in a new murine model of severe allergic conjunctivitis. *Cornea*. 2003;22:S13-S18.
- Munger RJ. Veterinary ophthalmology in laboratory animal studies. *Vet Ophthalmol*. 2002;5:167-175.
- Souza MC, Fialho SL, Souza PA, Fulgêncio GO, Da Silva GR, Silva-Cunha A. Tacrolimus-loaded PLGA implants: in vivo release and ocular toxicity. *Curr Eye Res*. 2014;39:99-102.
- Sakurai E, Nozaki M, Okabe K, Kunou N, Kimura H, Ogura Y. Scleral plug of biodegradable polymers containing tacrolimus (FK506) for experimental uveitis. *Invest Ophthalmol Vis Sci*. 2003;44:4845-4852.

27. Lee SS, Hughes P, Ross AD, Robinson MR. Biodegradable implants for sustained drug release in the eye. *Pharm Res*. 2010;27:2043-2053.
28. Peng Y, Ang M, Foo S, et al. Biocompatibility and biodegradation studies of subconjunctival implants in rabbit eyes. *PLoS One*. 2011;6:e22507.
29. Lu XL, Cai W, Gao ZY. Shape-memory behaviors of biodegradable poly(L-lactide-co-ε-caprolactone) copolymers. *J Appl Polym Sci*. 2008;108:1109-1115.
30. Zhang W, Prausnitz MR, Edwards A. Model of transient drug diffusion across cornea. *J Control Release*. 2004;99:241-258.
31. Niederkorn JY. Immune regulatory mechanisms in allergic conjunctivitis: insights from mouse models. *Curr Opin Allergy Clin Immunol*. 2008;8:472-476.
32. de Chigbu GI. The pathophysiology of ocular allergy: a review. *Cont Lens Anterior Eye*. 2009;32:3-15.
33. Bonini S, Bonini S, Lambiase A, et al. Vernal keratoconjunctivitis revisited: a case series of 195 patients with long-term followup. *Ophthalmology*. 2000;107:1157-1163.
34. Erdinest N, Solomon A. Topical immunomodulators in the management of allergic eye diseases. *Curr Opin Allergy Clin Immunol*. 2014;14:457-463.